

Hospital Management Committee

Mr. Samden Lama- Chairperson
Mr. Chandra Prasad Timilsena- Member
Mr. Sarad Adhikari- Member
Mr. Shiv Chandra Sah- Member
Mr. Bal Dhwoj Karki- Member

Mr. Mahendra Singh Rawal- Member
Mr. Shiv Kumar Pradhan- Member
Ms. Sophie Upadhyya- Member
Dr. Pramod Bahadur Shrestha- Member
Dr. Kailash Kumar Bhandari- Member Secretary

Congratulations

NEPAL ORTHOPAEDIC HOSPITAL

For

*Completing 27 Years of Selfless
Service !!!*

&

Striving to the Center of Excellence for Orthopaedic and Trauma Care

ROTARY CLUB OF PATAN

District 3292, Club No. 23126, Patan, Nepal



NDA- Nepal Orthopedic Hospital

Khagendra New Life Center

Gokarneshwor Municipality, 06, Jorpati, Kathmandu, Nepal

Tel: +977- 1-4911725, 4911274, 4910505

Email: neporth@mos.com.np, Website: www.noh.com.np

Message from Chairperson



NDA



NEPAL ORTHOPAEDIC HOSPITAL



शुभकामना

नेपाल अपाङ्ग संघ स्वर्गेन्द्र नवजीवन केन्द्रले आज भन्दा २७ वर्ष अगाडि देशको परिस्थितिलाई मध्यनजर गर्दै विशेष गरी अपाङ्गता भएका व्यक्तिहरुको जन्मजात, विभिन्न किसिमका रोग लागेर, त्यसैगरी दुर्घटना वा अन्य कारणबाट हाडजोर्नी तथा नशा सम्बन्धि समस्या भएकाहरुको उपचारका लागि अर्थोपेडिक अस्पतालको अत्यन्तै आवश्यकता रहेको महशुस गरी त्यसलाई पूरा गर्नका लागि यो नेपाल अपाङ्ग संघ नेपाल अर्थोपेडिक अस्पताल स्थापना गरिएको हो ।

१० वटा वेडबाट शुरु भएको अस्पताल आजको दिनसम्म १०० वेडको आधुनिक सुविधा सम्पन्न बनाउनका लागि अहोरात्र मेहनत गर्नुहुने नेपाल अपाङ्ग संघ स्वर्गेन्द्र नवजीवन केन्द्रका कार्यसमितिका अध्यक्षज्यूहरु, पदाधिकारीज्यूहरु, सदस्यज्यूहरु लगायत निर्देशक र सम्पूर्ण कर्मचारीज्यूहरु साथै अस्पताल सञ्चालक समितिका अध्यक्ष एवं सदस्यज्यूहरु, मेडिकल निर्देशकज्यू, अस्पतालका सम्पूर्ण डाक्टर, प्रशासन प्रमुख, प्रशासकिय अधिकृत नर्स तथा कर्मचारीहरु प्रति हार्दिक आभार व्यक्त गर्दछु ।

त्यसैगरी यस ने.अ.संघ नेपाल अर्थोपेडिक अस्पतालको विकास एवं विस्तारका लागि आर्थिक तथा भौतिक र अनुभवबाट अस्पतालको सेवालाई परिष्कृत बनाउनका लागि सहयोग गर्नुहुने नेपाल सरकार, अन्य राष्ट्रिय तथा अन्तर्राष्ट्रिय संघ/संस्थाहरु र व्यक्ति विशेषलाई समेत हार्दिक कृतज्ञता व्यक्त गर्न चाहन्छु ।

गोकर्णेश्वर नगरपालिकाले नगरभित्रका सम्पूर्ण नागरिकहरुलाई अर्थोपेडिक सम्बन्धि सेवा पुर्‍याउने उद्देश्यले नेपाल अर्थोपेडिक अस्पतालसंग सम्झौता गरी सो सम्बन्धि उपचार सेवा सहूलियत दरमा उपलब्ध गराइदै आइरहेकोमा गोकर्णेश्वर नगरपालिकाका नगर प्रमुख, उप प्रमुख जनप्रतिनिधिहरुको साथै नगरपालिका सम्पूर्ण कर्मचारीहरुलाई धन्यवाद दिदै आगामी दिनहरुमा नगरपालिकाबाट अस्पतालको वृद्धि विकासको लागि आर्थिक, भौतिक लगायतका सहयोग प्राप्त हुनेछ भन्ने आशा एवं विश्वास लिएको छु ।

देशकै गहनाको रूपमा रहेको ने.अ.संघ नेपाल अर्थोपेडिक अस्पतालले हाडजोर्नी सम्बन्धि समस्या भएका बिरामीहरुका लागि आगामी दिनहरुमा थप गुणस्तरीय सेवा विस्तार गर्दै लैजानका लागि अत्यावश्यक उपकरण तथा सो सम्बन्धि दक्ष जनशक्तिको ब्यवस्था गरी सेवा प्रवाह गर्ने एक विशेष अर्थोपेडिक अस्पतालको परिचय दिन सक्ने बनाउनका लागि आर्थिक तथा भौतिक रूपमा सहयोग गर्न नेपाल सरकार, अन्तर्राष्ट्रिय जगत र सम्पूर्ण दाता महानुभावहरुलाई हार्दिक अनुरोध गर्दै अस्पतालको २७औं वार्षिक उत्सवको उपलब्धमा पुनः सबैलाई धन्यवाद दिदै शुभकामना व्यक्त गर्दछु ।

सार्वदेन लामा

अध्यक्ष

नेपाल अपाङ्ग संघ

नेपाल अर्थोपेडिक अस्पताल



Message from Medical Director



NDA



NEPAL ORTHOPAEDIC HOSPITAL



Dear colleagues, partners, patient and well wishers,

Namaste,

It gives me immense pleasure and pride to extend my heartfelt greetings to you all as we celebrate the 27th anniversary of Nepal Disabled Association-Nepal Orthopaedic Hospital.

Over the past 27 years this institution has stood as a symbol of hope and healing for thousands of people across the country. From humble beginnings to becoming a leading center for orthopaedic care, our journey has been marked by dedication, compassion and commitment to excellence.

This milestone is not just a celebration of time. It is a celebration of countless lives transformed through timely surgeries, rehabilitation and compassionate care, it is a tribute to our founding visionaries, hardworking staff, dedicated doctors, nurses and the continued trust of our patients and their families.

As we look to the future, our focus remains an expanding access to quality orthopaedic service at affordable cost, strengthening training and research and embracing innovation to better serve the people of Nepal.

Let us renew our commitment to serve with integrity empathy and professionalism. Together we will continue to uphold the legacy of Nepal Disabled Association- Nepal Orthopaedic Hospital and reach greater heights in patient care.

Thank you for being part of this remarkable journey.

With regards

Dr. Kailash Kumar Bhandari,

Medical Director,

Nepal Orthopaedic Hospital

14th August, 2025





Best Wishes to NOH

Dear friends,

During a quarter of a century, our non-profit institute went through a significant development, reached a high level of excellence, and became a benchmark that no longer can be missed.

Our Center of Excellence for Orthopedic and Trauma Care became an amazing project, thanks to its dedicated staff and leaders!

Your tremendous efforts helped and cured lots of needy people.

As a non-profit institute we must continue this way of serving our community.

Let me thank once again NOH medical director Dr Kailash Kumar Bhandari and his staff for their never lasting commitment to execute their job with great intensity and professionalism.

You are our inspiration to move forward, to serve above self, and to help all our patients, the deprived and needy ones in particular! We are very grateful as well to all our NOH well-wishers!

With 'a special thank you' to the many Rotary clubs, Rotary districts, fellow Rotarians, and the Rotary Foundation whose contributions brought the Nepal Orthopedic Hospital to one of most outstanding humanitarian projects within Rotary International.

We do not forget to thank the Government of Nepal who became a great partner, supporting NOH to achieve its mission, to improve the quality of life of thousands of Nepalese.

Let us continue to work together to help even more people! This is my message to all of you.

And do not forget dear friends, enjoy life!!!

Luc Salens

Board advisor.

Member of Rotary Club Maldegem- District 2130



Best Wishes

Nepal Orthopedic Hospital on its 27th Anniversary



Rtn. Khadak Singh Bisht
President, Rotary Club of Patan (2025–2026)

On behalf of the Rotary Club of Patan (RCP), I extend my heartfelt congratulations to Nepal Orthopaedic Hospital (NOH) on completing 27 years of outstanding service in orthopedic and trauma care. This remarkable journey is a tribute to the vision and commitment of its founders, partners, dedicated medical team, and generous supporters who have worked together to bring healing and hope to thousands.

Over the years, NOH has become a symbol of compassion and medical excellence. Each patient treated, each life restored, reflects the team’s tireless efforts and unwavering dedication to the well-being of all, especially those in greatest need.

The Rotary Club of Patan is proud to be a longstanding partner in your noble mission. Your values of service, care, and inclusion deeply resonate with the Rotary spirit. As you move forward, we are confident that NOH will continue to shine as a center of excellence, reaching more lives and advancing orthopedic care across Nepal.

Thank you for your continued commitment to humanity. We stand with you in your journey ahead.

With warm regards,

Khadak

Rtn. Khadak Singh Bisht
President (2025–2026)
Rotary Club of Patan



NOH STAFF

Doctor

S.N.	Name	Designation
1	Dr. Kailash Kumar Bhandari	Medical Director
2	Dr. Muktinath Timilsina	Deputy Medical Director
3	Dr. Prakash Gyawali	Sr. Const. Orthopaedic Surgeon
4	Dr. Yubaraj Kharel	Sr. Const. Orthopaedic Surgeon
5	Dr. Samyukta Acharya	Sr. Consultant Anaesthesiologist
6	Dr. Sunil Badgami	Sr. Consultant Anaesthesiologist
7	Dr. Rachit Sharma	Consultant Orthopaedic Surgeon
8	Dr. Sujan Man Singh	Registrar Orthopaedic Surgeon
9	Dr. Rajiv Psd Shrestha	Registrar Orthopaedic Surgeon
10	Dr. Anil Ghimire	Registrar Orthopaedic Surgeon

S.N.	Name	Designation
11	Dr. Mandeep Karki	Registrar Orthopaedic Surgeon
12	Dr. Anish Gyawali	Registrar Orthopaedic Surgeon
13	Dr. Samir Karki	Registrar Orthopaedic Surgeon
14	Dr. Rama Shankar Gupta	Orthopaedic Surgeon
15	Dr. Sumit Lohia	Orthopaedic Surgeon
16	Dr. Bijendra Dangol	Orthopaedic Surgeon
17	Dr. Sarthak Nepal	Orthopaedic Surgeon
18	Dr. Sripur Manandhar	Orthopaedic Surgeon
19	Dr. Bishwas Pokhrel	Orthopaedic Surgeon

Administration

S.N.	Name	Designation
1	Shyam Prasad Rupakheti	Chief Administrator
2	Saroj Satyal	Sr. Account Officer
3	Dhiraj Mainali	Sr. Administrative officer
4	Ghanshyam Neupane	Sr. Office Assistant
5	Sangita Thakuri	Sr. Office Assistant
6	Suman Bhandari	Sr. Office Assistant

S.N.	Name	Designation
7	Harikala Kandel	Sr. Office Assistant
8	Bivek Kumar Pokharel	Sr. Office Assistant
9	Sitaram Dangal	Sr. Office Assistant
10	Sujita Singh	Sr. Office Assistant
11	Himal Singh Lama	Sr. Office Assistant
12	Puja Bhattarai	Sr. Office Assistant

Nursing

S.N.	Name	Designation
1	Meena Gurung	Matron
2	Suman BC	Nursing Supervisor
3	Anita Gurung	Nursing Supervisor
4	Meena Thapa	Sister
5	Rolina Karki	Sister
6	Sita Tripathi	Sister
7	Kalpna Panta	Staff Nurse Officer
8	Srijana Sapkota	Sr. Staff Nurse
9	Anita Budathoki	Sr. Staff Nurse
10	Santoshi Mali	Sr. Staff Nurse
11	Reniya Shrestha	Sr. Staff Nurse

S.N.	Name	Designation
12	Tara Ghimire	Sr. Staff Nurse
13	Kalpna K.C.	Sr. Staff Nurse
14	Merina Karki	Sr. Staff Nurse
15	Sony Lama	Sr. Staff Nurse
16	Luna Bhattarai	Sr. Staff Nurse
17	Sita Dahal	Sr. Staff Nurse
18	Babita Karki	Sr. Staff Nurse
19	Pratima Gautam	Sr. Staff Nurse
20	Aruna Maharjan	Sr. Staff Nurse
21	Sachina Khadka	Sr. Staff Nurse
22	Roshani Maharjan	Sr. Staff Nurse



S.N.	Name	Designation
23	Sambina Shrestha	Sr. Staff Nurse
24	Sushma Shrestha	Sr. Staff Nurse
25	Anju Tachamo	Sr. Staff Nurse
26	Binita Zimba Lama	Sr. Staff Nurse
27	Sunita Nepal	Sr. Staff Nurse
28	Sangita Upadhyaya	Sr. Staff Nurse
29	Jaya Kuinkel	Sr. Staff Nurse
30	Binita Thapa	Sr. Staff Nurse
31	Sujata Gurung	Sr. Staff Nurse
32	Pramisha Shrestha	Sr. Staff Nurse
33	Sadikshya Bata Shrestha	Sr. Staff Nurse
34	Smriti Adhikari	Sr. Staff Nurse
35	Rupa Dhungana	Staff Nurse

S.N.	Name	Designation
36	Pabina Baral	Staff Nurse
37	Bandana Pudasaini	Staff Nurse
38	Shristi Tamang	Staff Nurse
39	Rachana Mainali	Staff Nurse
40	Prakriti GC	Staff Nurse
41	Rashila Simkhada	Staff Nurse
42	Smrity Tamang	Staff Nurse
43	Asha Kathayat	Staff Nurse
44	Chinta Devi Oli	Staff Nurse
45	Shila Lamichhane	Staff Nurse
46	Ashrika Thapa	Staff Nurse
47	Damar Kumari Gurung	Staff Nurse

Laboratory

S.N.	Name	Designation
1	Pawan Kumar Chhetri	Lab Technologist
2	Suman Silwal	Sr. Lab Technician
3	Roshani Ghimire	Sr. Lab Technician

S.N.	Name	Designation
4	Sudhir Chandra Adhikari	Lab Technician
5	Ram Shrestha	Sr. Lab Assistant
6	Sushmita Shrestha	Lab Assistant

Emergency

S.N.	Name	Designation
1	Laxman Gyawali	Sr. CMA
2	Kedar Raj Giri	Sr. CMA
3	Kailash Chandra Lama	Sr. CMA

S.N.	Name	Designation
4	Sudeep Chalise	Sr. CMA
5	Bikash Joshi	Sr. CMA

Physiotherapy

S.N.	Name	Designation
1	Ramesh Sada	Sr. Physiotherapist
2	Suraj Khanal	Sr. Physiotherapist
3	Alok Kumar Jha	Sr. Physiotherapy Assistant

S.N.	Name	Designation
4	Goma Thapa	Sr. Physiotherapy Assistant
5	Rakshya KC	Sr. Physiotherapy Assistant

Radiology

S.N.	Name	Designation
1	Narendra Chaudhary	Radiographer officer
2	Amit Gautam	Radiography Technologist
3	Ratna Bahadur Shahi	Sr. Radiographer
4	Manju Rishi Jaisi	Sr. Radiographer

S.N.	Name	Designation
5	Prakash Simkhada	Radiographer
6	Sushil Maharjan	Sr. Dark Room Operator
7	Shyam Maharjan	Sr. Dark Room Operator

**Pharmacy**

S.N.	Name	Designation
1	Bina Upadhyay	Sr. Pharmacy Assistant
2	Radhika Khagi	Sr. Pharmacy Assistant
3	Chandra Jyoti Shakya	Sr. Pharmacy Assistant
4	Anil Shrestha	Sr. Pharmacy Assistant

S.N.	Name	Designation
5	Dinesh Basnet	Sr. Pharmacy Assistant
6	Subindra Shakya	Pharmacy Staff
7	Prajesh Neupane	Pharmacy Assistant

Maintenance

S.N.	Name	Designation
1	Dhurba Giri	Sr. Electrician
2	Som Prasad Upadhyay	Sr. Bio-med Assistant

S.N.	Name	Designation
3	Ramesh Sapkota	Sr. Plumber

Driver

S.N.	Name	Designation
1	Dil Bahadur Thapa	Sr. Driver
2	Ramu Khanga	Sr. Driver

S.N.	Name	Designation
3	Sagar Thapa	Driver
4	Baburam Khatri	Driver

Helper

S.N.	Name	Designation
1	Sabitri Dulal	Sr. CSSD Assistant
2	Rajan Dulal	Sr. Helper
3	Dharma Das Chaudhari	Sr. Helper
4	Parbati Karki	Sr. Helper
5	Nayandra Baral	Sr. Helper
6	Lok Nath Badal	Sr. Helper
7	Pabitra Timilsina	Sr. Helper
8	Krishna Kumari Ghimire	Sr. Helper
9	Devlal Pode	Sr. Helper
10	Kumari Majhi	Sr. Helper
11	Manahari Dahal	Sr. Helper
12	Dharma Raj Ghimire	Sr. Helper
13	Gopal Pudasaini	Sr. Helper
14	Radhika Acharya	Sr. Helper

S.N.	Name	Designation
15	Kedar Nath Poudel	Sr. Helper
16	Ajita Karki	Sr. Helper
17	Bhakta Bdr. Karki	Sr. Helper
18	Ramila Shrestha	Sr. Helper
19	Rama Pandit	Sr. Helper
20	Meena Choudhari	Sr. Helper
21	Saraswati Chalishe	Sr. Helper
22	Bharat Kr. Lama	Sr. Helper
23	Saraswati Uprety	Sr. Helper
24	Laxmi Chaulagain	Sr. Helper
25	Yemu Maya Magar	Sr. Helper
26	Brindha Sharma Bhandari	Sr. Helper
27	Til Maya Gautam	Sr. Helper

Visiting Staffs

S.N.	Name	Designation
1	Dr. Sabin Gauchan	Const. Anaesthesiologist
2	Dr. Rupesh Yadav	Const. Anaesthesiologist
3	Dr. Ashish Ratna Bajracharya	Const. Anaesthesiologist
4	Dr. Ujjit Kumar Karmacharya	Const. Cardiologist
5	Dr. Sushil Dulal	Const. Radiologist

S.N.	Name	Designation
6	Dr. Krishna Budathoki	Const. Radiologist
7	Dr. Shradha Koirala	Const. Pathologist
8	Dr. Santosh Gautam	Const. Physician
9	Dr. Durga Thapa	Const. Psychiatrist
10	Kshitij Gartoulla	Senior Pharmacist



शुभकामना

ने.अ.सं-नेपाल अर्थोपेडिक अस्पतालको २७ औं वार्षिकोत्सवको सुखद उपलक्ष्यमा अस्पताल परिवारलाई हार्दिक मंगलमय शुभकामना व्यक्त गर्न चाहन्छौं । हाडजोर्नी उपचारमा एक अलग्गै पहिचान बनाउन सफल तथा विशिष्टिकृत सेवा दिने यस अस्पतालले निरन्तर सर्वशुलभ, जनमुखि तथा गुणस्तरीय सेवा प्रदान गर्ने अस्पताल बनोस भन्ने अपेक्षा सहित हार्दिक शुभकामना व्यक्त गर्दछौं ।

इम्पोर्ट हाउस नेपाल प्रा.लि

महाराजगंज , काठमाडौं

शुभकामना

ने.अ.सं-नेपाल अर्थोपेडिक अस्पतालको २७ औं वार्षिकोत्सवको सुखद उपलक्ष्यमा अस्पताल परिवारलाई हार्दिक मंगलमय शुभकामना व्यक्त गर्न चाहन्छौं । हाडजोर्नी उपचारमा एक अलग्गै पहिचान बनाउन सफल तथा विशिष्टिकृत सेवा दिने यस अस्पतालले निरन्तर सर्वशुलभ, जनमुखि तथा गुणस्तरीय सेवा प्रदान गर्ने अस्पताल बनोस भन्ने अपेक्षा सहित हार्दिक शुभकामना व्यक्त गर्दछौं ।

सियोर हेल्थ नेपाल प्रा.लि.

ललितपुर

शुभकामना

ने.अ.सं-नेपाल अर्थोपेडिक अस्पतालको २७ औं वार्षिकोत्सवको सुखद उपलक्ष्यमा अस्पताल परिवारलाई हार्दिक मंगलमय शुभकामना व्यक्त गर्न चाहन्छौं । हाडजोर्नी उपचारमा एक अलग्गै पहिचान बनाउन सफल तथा विशिष्टिकृत सेवा दिने यस अस्पतालले निरन्तर सर्वशुलभ, जनमुखि तथा गुणस्तरीय सेवा प्रदान गर्ने अस्पताल बनोस भन्ने अपेक्षा सहित हार्दिक शुभकामना व्यक्त गर्दछौं ।

मेडिएड नुराज

बाघदरवार, काठमाडौं

MAJOR EVENTS 2024

NOH family wants to express sincere gratitude to CWIN for donating 30 piece Blankets for children ward admitted patients

Thanks for the generous support and we expect similar gesture in forthcoming days.



Dr. Kailash Kumar Bhandari, Medical Director of NOH had a valuable discussion with Ms. Tessa de Waard representative of One of the Valuable donors (Stichting Nepal and Wilde Ganzen Foundation) of NOH



Medical Services provided by NOH on programme organized by Spinal cord Injury Network Nepal. Special Thanks to Mr. Sudip Chalise of Emergency Department of Hospital.



Technical support from NOH on programme organized by BIA



135th International Labour Day



International World Hand Hygiene Day May 05, 2024



Farewell program, retirement of Ms. Tilmaya Gautam and Mr. Raman Damai



बागमती प्रदेशका पूर्वमुख्यमन्त्री पौडेल नेपाल अर्थोपेडिक अस्पतालमा



बागमती प्रदेशका पूर्वमुख्यमन्त्री डोरमणी पौडेलले काठमाडौंको जोरपाटीस्थित नेपाल अपाङ्ग सङ्घ नेपाल अर्थोपेडिक अस्पतालको अवस्थाबारे जानकारी लिनुभएको छ । पौडेलले अस्पताल बागमती प्रदेशको गौरव भएको जनाउँदै निरन्तर सहयोग रहने प्रतिबद्धता जनाउनु भयो । उहाँले आफु मुख्यमन्त्री रहेका बेला सक्दो सहयोग गरेको स्मरण गर्दै हाल पनि बागमती सरकारले त्यसलाई निरन्तरता दिएको बताउनु भयो । सो अबसरमा अस्पतालका मेडिकल निर्देशक डा कैलाश भण्डारीले अस्पतालको अबस्था बारे जानकारी गराउनु भएको सुचना अधिकारी धीरज मैनालीले जानकारी दिनुभयो ।

Honorable Shekhar Koirala Visited NDA-NOH. Dr. Kailash Bhandari, Medical Director welcomed and explained about services available at hospital.

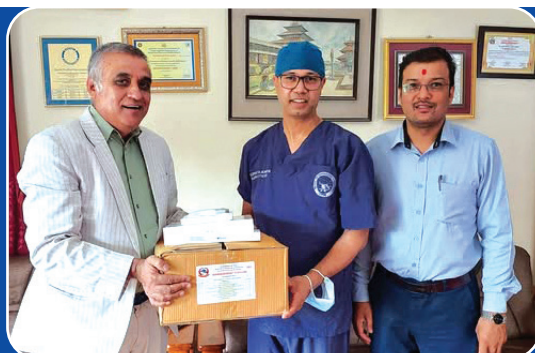नेपाल अर्थोपेडिक अस्पताललाई सरकारले दिने आर्थिक सहयोगको निरन्तरताका लागि पहल गर्छु: डा कोइराला



नेपाली कांग्रेसका नेता डा कोइरालाले नेपाल अपाङ्ग सङ्घ अन्तर्गत संचालित नेपाल अर्थोपेडिक अस्पताललाई संघीय सरकारले दिने आर्थिक र अन्य सहयोगको निरन्तरता दिन पहल गर्ने बताएका छन् । उक्त अस्पतालको अवलोकन गर्दै डा कोइरालाले प्रदेश र स्थानीय सरकारले अस्पतालमा निमुखा र गरिब जनतको गुणस्तरीय हाडजोर्नी उपचारमा लगानी बढाउनुपर्ने बताए। अस्पतालको निरीक्षणपश्चात नेता डा कोइरालाले अर्थोपेडिक उपचारसँगै स्नातकोत्तर तहको अध्ययन गर्ने शिक्षण संस्थाका रूपमा यस अस्पतालको विकास गर्दै लैजानुपर्ने बताउनुभएको हो ।

Handover of USG machine to Dr. Samyukta Acharya (HoD) Anesthesia Department, Donated by Management Division, Department of Health Services, Ministry of Health and Population.

Special Thanks to Director of Management Division for the generous support



Dr. Kailash Kumar Bhandari Medical Director of NDA- Nepal Orthopedic Hospital welcoming and providing Token of Love to Deligates from Rotary Club of Damme, Belgium.



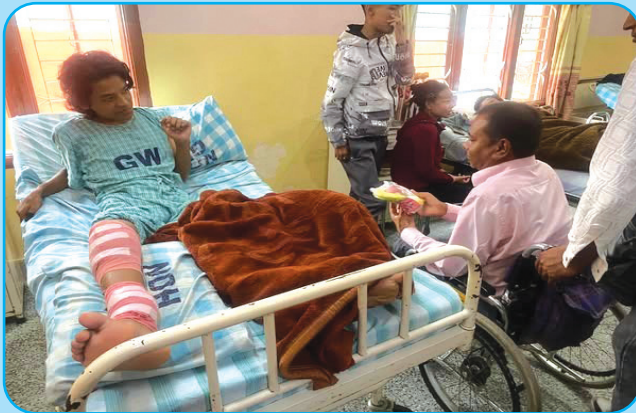The Belgian Rotarians of the Rotary Club of Maldegum Belgium have promised to support Nepal Disabled Association Nepal Orthopedic Hospital in Jorpati, Kathmandu.

A team of Rotarians visited the hospital and discussed about the modalities of support, including technical and financial support.

The former president of the Rotary Club of Maldegum Belgium, Johan, mentioned that the Rotarians have an emotional connection with this hospital and promised to help.

In the program, Dr. Kailash Bhandari, the medical director of the hospital, informed about the services provided by the hospital along with the programs conducted with the help of supporting organizations.

26th Anniversary celebration of NDA- Nepal Orthopedic Hospital





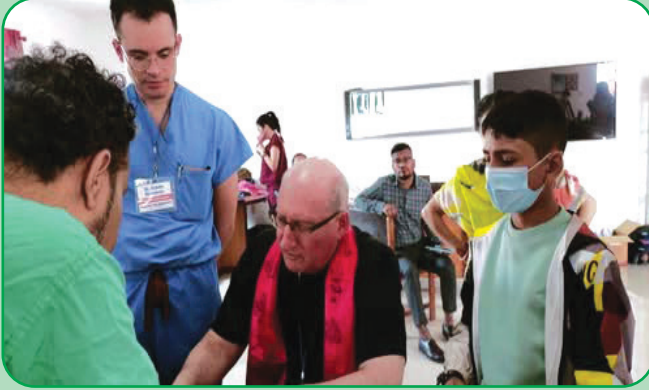Meeting at WVAf with Krijn de Best, Chairperson of Stitching Nepal, Neitherland



Healing the Children Mission Camp at NOH

HEALING THE CHILDREN, USA conducted free Foot and Ankle camp at NDA- Nepal Orthopaedic Hospital from 2024/04/07 to 2024/04/11. Poor, Ultra Poor and marginalized people with foot and ankle health problem got benefitted from the camp.

असहाय र विपन्नका लागि हाडजोर्नी सम्बन्धी निःशुल्क स्वास्थ्य शिविर



नेपाल अपाङ्ग सङ्घ नेपाल अर्थोपेडिक अस्पतालमा गरिब र असहाय व्यक्तिहरूका लागि खुट्टाको हड्डीको उपचारसम्बन्धी निःशुल्क स्वास्थ्य शिविर आयोजना गरिएको छ । हिलिड द चिल्ड्रेन अमेरिकाका विशेषज्ञ चिकित्सकहरू अलिरेजा खोसरोबादी र जोहन हर्जेनबर्ग सहित अस्पतालका विशेषज्ञ चिकित्सकको टोलीले उपचार दिनेगरी शिविरको आयोजना गरिएको छ । यस निःशुल्क स्वास्थ्य शिविरबाट आर्थिक अभाव भएका गरिब तथा विपन्न व्यक्तिहरूले लाभ लिनुभयो । यस स्वास्थ्य शिविरमा सामान्य स्वास्थ्य परीक्षणदेखि जटिलखालका शल्यक्रियाहरू पनि गरिने भएको छ । यसप्रकारको जटिल शल्यक्रियामा विशेषज्ञ चिकित्सकहरू सहभागी भए । यस शिविरबाट खुट्टाको हड्डी बाङ्गो भएका, हाड तथा जोर्नीसम्बन्धी जन्मजात विविध समस्या भएका, पछि समस्या उत्पन्न भएका तर समयमै उपचार पाउन नसकेका तथा शल्यक्रिया गर्नुपर्ने भए पनि विशेषज्ञ चिकित्सकको परामर्श पाउन नसकेकाहरूले लाभ लिनुभयो ।

MoU between NDA- Nepal Orthopedic Hospital and Employee Provident Fund for registration of hospital at EPF Health Scheme.



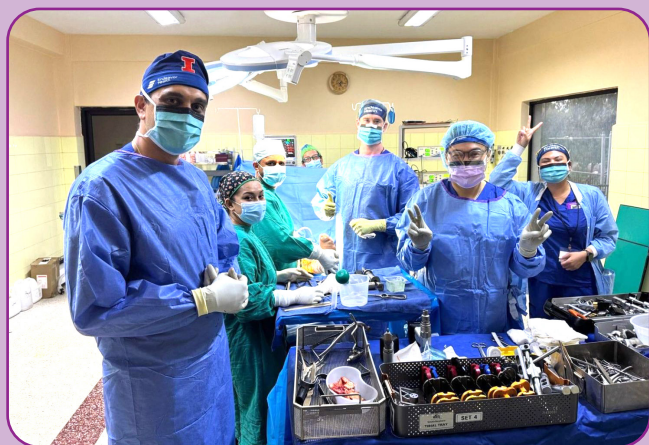Operation Walk Chicago Mission camp at NOH

Knee surgery performed on 34 patients

Nepal Orthopedic Hospital has performed knee surgery on 34 patients. A team of specialist doctors supported by the Operation Walk Chicago in the United States (US) performed surgeries on 43 knees of 34 patients in five days at Nepal Orthopaedic Hospital.

The surgery was carried out on the patients who had long been suffering from knee pain.

OP walk Chicago, USA has been collaborating with the orthopedic hospital since 2009 and so far about 600 knee surgeries have been performed.



नेपाल अर्थोपेडिक अस्पताल जोरपाटीमा सिकागोबाट आएको विदेशी डाक्टरहरूको टिमलाई स्वागत । हरेक वर्ष शिविर स्वरूप बिरामीहरूको घुँडाको हड्डी फेर्न उपचारको लागि विदेशी डाक्टरको टिम आउने गर्दछ सोही अनुसार यस वर्ष पनि सोही कार्यको लागि आएका सो ग्रुपलाई गोकर्णेश्वर नगरपालिकाका मेयर दिपक रिसाल, खगेन्द्र नवजीवन केन्द्रका अध्यक्ष सामदेन लामा सहित अस्पतालले स्वागत गरेको हो ।



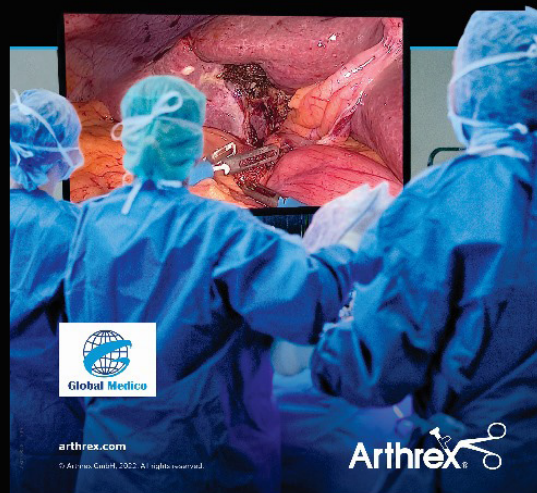Synergy^{UHD4}

Maximum Resolution. Maximum Color. Maximum Results.

4K

ULTRA HD

- Ultra-high resolution camera system, LED light source and image management system all combined in one housing, with intuitive tablet controller
- Clarity and detail due to more than one billion colors
- Monitor sizes up to 55"
- Interdisciplinary solutions



Global Medico Pvt. Ltd.

New Baneshwor, Kathmandu | Ph.: 01-5245148

शुभकामना

ने.अ.सं-नेपाल अर्थोपेडिक अस्पतालको २७ औं वार्षिकोत्सवको सुखद उपलक्ष्यमा अस्पताल परिवारलाई हार्दिक मंगलमय शुभकामना व्यक्त गर्न चाहन्छौं । हाडजोर्नी उपचारमा एक अलग्गै पहिचान बनाउन सफल तथा विशिष्टिकृत सेवा दिने यस अस्पतालले निरन्तर सर्वशुलभ, जनमुखि तथा गुणस्तरीय सेवा प्रदान गर्ने अस्पताल बनोस भन्ने अपेक्षा सहित हार्दिक शुभकामना व्यक्त गर्दछौं ।

मास मेडिलिन्क

काठमाण्डौ

Free Orthopaedic Surgical Camp

District Hospital, Doti
18th-22nd February, 2024



Organized by

Rotary Club of Kathmandu West
NDA- Nepal Orthopaedic Hospital, Jorpati, Kathmandu
Dipayal Silgadhi Municipality
District Hospital, Doti

Sponsored by

Med-Solution Foundation, Switzerland

PREFACE

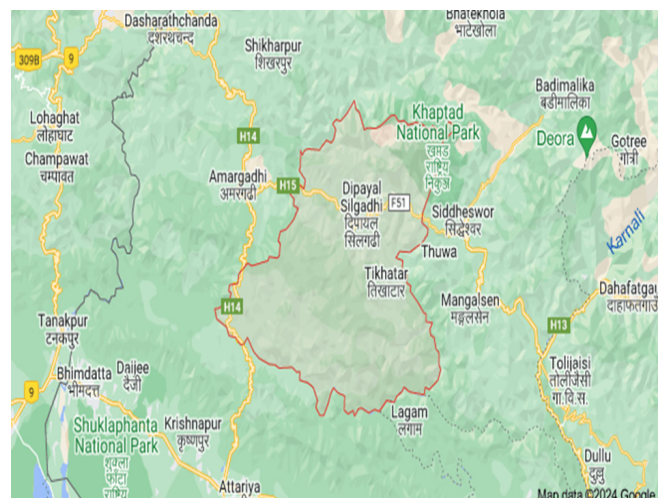Nepal Orthopaedic Hospital is a charitable and one of the best trauma center situated at Gokarneshwor, Kathmandu, Nepal. It was established on August 1998. From the very beginning, this hospital is providing orthopaedic service to the needy patients from all over Nepal. This hospital has organized many free OPD and surgical camps in various remote and rural areas of Nepal in association with Med Solution Foundation, Switzerland.

INTRODUCTION

Doti district is a part of sudurpashchim province. It is one of the 77 districts of Nepal with Silgadhi as its headquarter. It covers an area of 2,025

square kilometer with a population of 205,683 in year 2021. The name Doti is believed to have originated from the word Doab which means the land area between the confluence of two rivers, in the west river Kali bordering Kumaon division of Uttarakhand and the Karnali river in the east.

Dotiyali is the local language spoken in Doti region which is similar to the Kumauni language, a language spoken by people of Kumaon, a state in modern-day India, Nepal's neighbouring country.



Center of Excellence for
Orthopaedic and Trauma Care

TEAM MEMBERS

- | | |
|--|---|
| 1. Dr. Prakash Gyawali - Senior Consultant Orthopaedic Surgeon | 8. Rolina Karki — Sister |
| 2. Dr. Sunil Badgami — Senior Consultant Anesthesiologist | 9. Sambina Shrestha — Senior Staff Nurse |
| 3. Dr. Anil Ghimire — Registrar Orthopaedic Surgeon | 10. Binita Jimba Lama — Senior Staff Nurse |
| 4. Dr. Mandeep Karki — Registrar Orthopaedic Surgeon | 11. Smriti Tamang — Staff Nurse |
| 5. Dr. Anish Gyawali — Registrar Orthopaedic Surgeon | 12. Bivek Kumar Pokhrel — Admin Assistant |
| 6. Dr. Bijendra Dangol — Orthopaedic Surgeon | 13. Subindra Shakya — Pharmacist |
| 7. Anita Gurung — Nursing Supervisor | 14. Salyan Tamang — Operation Theatre Assistant |

Purpose of the camp:

1. To provide free orthopaedic and trauma treatments to the poor and needy patients of Doti district, who are not capable to go to big hospitals for treatment.
2. Provide better opportunity for the doctors and nurses to develop skills and practice of working in limited facility setup.
3. To enhance local awareness about the damage prevention measures caused due to trauma and thereby preventing and controlling deformity and disability.
4. To provide an opportunity for local doctors and health workers to learn basic principles of trauma management.
5. To observe the cultural and geographical identities of Doti in relation to health politics.

Objectives

1. To perform at least 60 to 70 free surgeries including deformity correction, fresh trauma, hand reconstruction and plastic surgeries.
2. To carry out at least 1300 OPD checkups and provide free medications including free steroid injections.
3. To publicize Nepal Orthopaedic hospital as one of the best trauma center in Nepal.

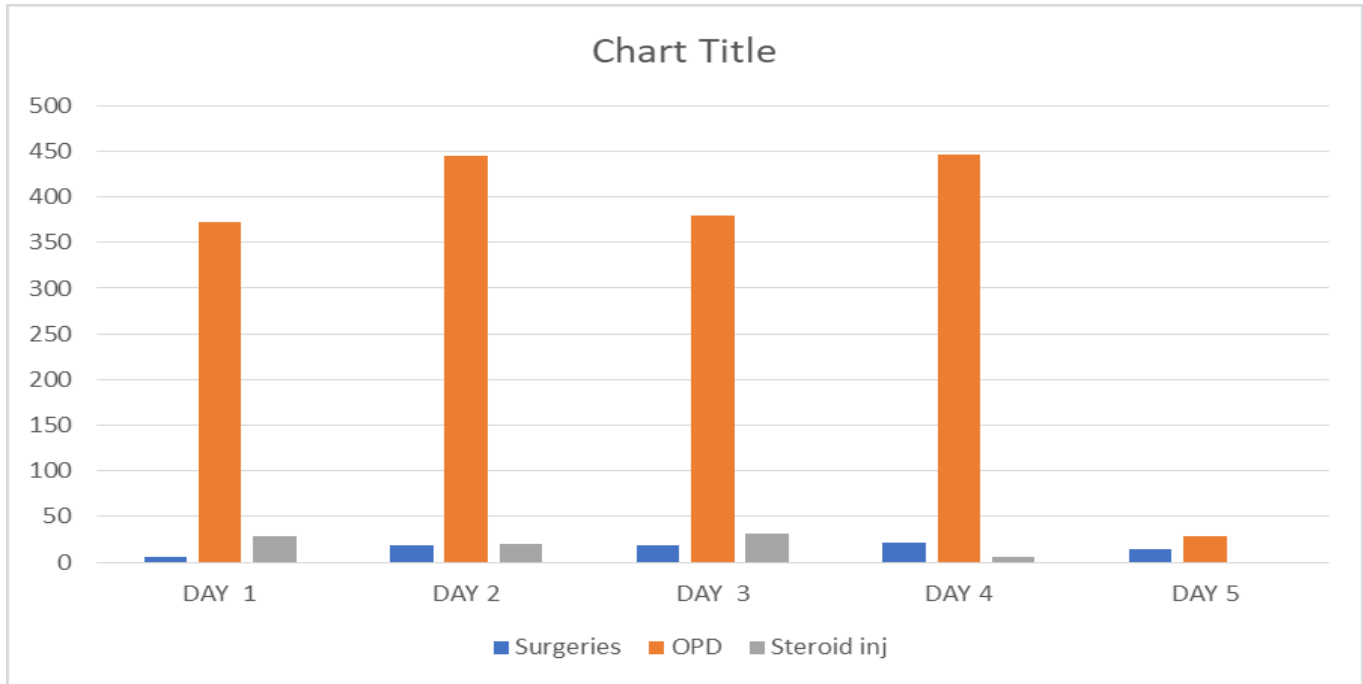
ACHIEVEMENTS

During 5 days of Free Orthopaedic Surgical camp, Total 77 cases underwent free surgery which includes deformity corrections, contracture release, hand surgeries, fresh traumatic fractures, excisions and implant removal.

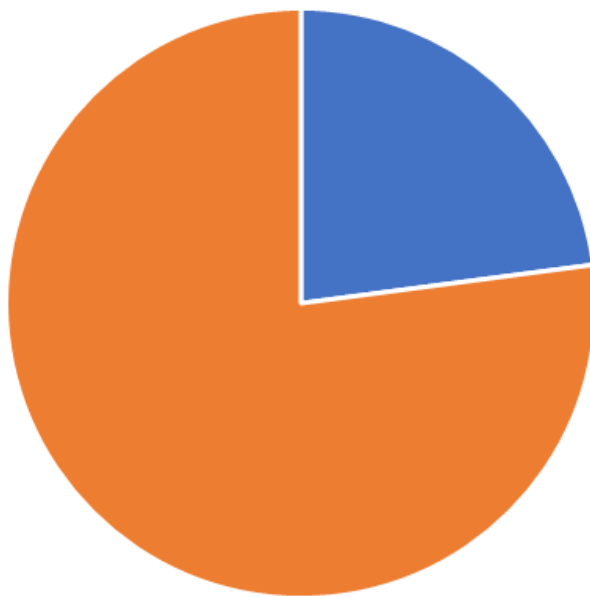
Total 1785 patients received free OPD check ups and free oral medications and we provided free steroid injections to 127 patients, most of them were with Osteoarthritis knee joint, Frozen shoulders, Tennis Elbow, Plantar fasciitis.

LIST OF SURGERIES DONE

Fresh trauma.....	16	Deformity correction	8
Implant removal.....	24	Slab/cast application	14
Hand and plastic surgery	12	Steroid injections	127
Excision	12		

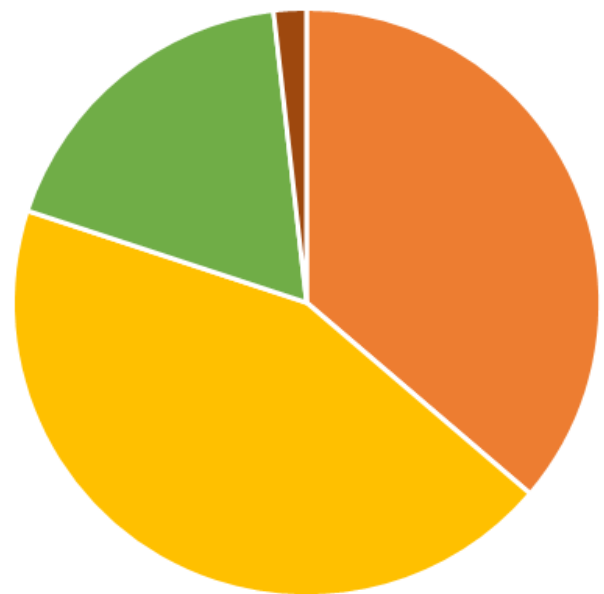


GENDER



■ MALE ■ FEMALE ■

AGE GROUPS



■ 0-15 YRS ■ 16-30 YRS ■ 31-50 YRS ■ 50+ YRS

CONCLUSION

To conclude, this camp is equally effective and successful camp organized by Rotary Club of Kathmandu West and NDA- Nepal Orthopaedic Hospital, Jorpati, Kathmandu, which was sponsored by Med-Solution Foundation, Switzerland. Thanks to the local authorities of Doti district, the entire Doti hospital team, Doti police, Army, APF and to every personal directly or indirectly involved in this camp to make this camp possible and successful. Thank you.

Report of Free Orthopaedics Surgical Camp

Ramechhap Hospital, Ramechhap, Bagmati Province, Nepal
(August 28, 2024 to August 31, 2024)




Background:

A free surgical camp was organized at Ramechhap hospital from August 28, 2024 to August 31, 2024. The camp was jointly organized with financial assistance of Med-Solution Foundation St. Moritz Switzerland, Rotary Club of Kathmandu West, NDA-Nepal Orthopaedic Hospital (NOH), Ramechhap Municipality, and Ramechhap Hospital. The surgical team, equipment and the logistics of the camp were supported and managed by Nepal Orthopaedic Hospital.

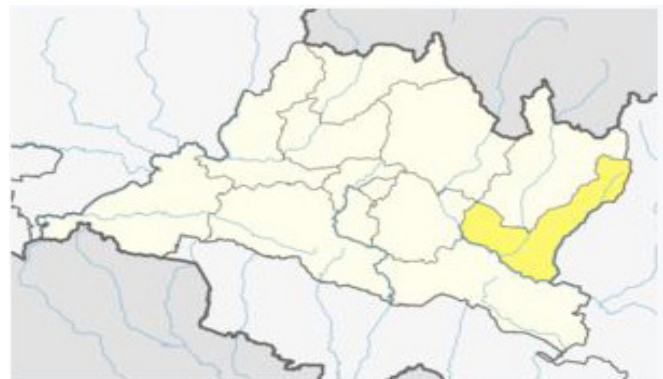The Organizations involved in the camp were:

- Med-Solution Foundation, St. Moritz, Switzerland
- Rotary Club of Kathmandu West
- NDA-Nepal Orthopaedic Hospital (NOH)
- Ramechhap Municipality
- Ramechhap Hospital, Ramechhap district

Ramechhap Background:



Panch Pokhari at Ramechhap



Location of district in province

Ramechhap District, a part of Bagmati Province, is one of Nepal's seventy-seven districts and situated in the hilly region of the country. The district, also known as Wallo Kirat Ramechhap, has its district headquarters in Manthali and covers an area of 1,546 km² (597 sq mi). In 2011, the district had a population of 202,646 and population density of 137.4 per km² (53.1 per sq mi). It stretches from the Sun Koshi River to the base of the Everest range, with elevations varying from 488 m at the Sun Koshi to Numburchuli peak at 6,909 m. The district is bordered by Dolakha to the north, Okhaldhunga and Khotang to the east, Sindhuli to the south, and Kavrepalanchok and Sindhupalchok to the west. The Tamakoshi River, a major tributary of the Sunkoshi River, runs through the district, providing water resources and playing a vital role in local agriculture and hydroelectric power generation.

Ramechhap District is primarily connected to the rest of Nepal via the BP Highway, also known as the Banepa-Sindhuli-Madhesh Highway. This highway links Ramechhap to Kathmandu, the capital city, through Sindhuli District, providing crucial access to trade, transportation, and communication. Additionally, local roads from the district center, Manthali, connect with the BP Highway, making travel and logistics between Ramechhap and other parts of the country more convenient. Ramechhap terrain is diverse, consisting of steep hills, valleys, rivers, and forested areas. The district's climate varies from subtropical in the lower regions to temperate in the higher altitudes. Agriculture is the mainstay of the local economy, with crops like rice, maize, and millet being cultivated in terraced fields. Despite its rugged landscape, the district is home to

vibrant rural communities and offers access to some trekking routes, which showcase its natural beauty. Ramechhap District has the highest population of the endangered native group the Kusunda and the lowest population growth rate in Nepal.

Access to health services in Ramechhap District is limited due to its hilly terrain and rural nature. There are a few government-run health posts, primary healthcare centers, and one district hospital in Ramechhap. The district hospital provides basic medical services, including outpatient care, maternal and child health services, and limited emergency care. However, specialized medical treatment and advanced facilities are often unavailable, requiring patients to travel to nearby cities like Kathmandu for more comprehensive care. Hence, Orthopaedic surgical camp such as this one would contribute a lot to enhancing access to quality health services to people of Ramechhap.

Objective of the camp:

1. To give free specialized orthopaedics and trauma care
2. To provide free surgeries to physically challenged people (deformity correction, Hand plastic reconstructive surgery, contracture release surgeries and trauma related surgeries)
3. Free OPD consultation and free medications
4. To enhance public awareness about the damage prevention measures after trauma thereby preventing deformity and disability. Train local doctors and health worker about basic orthopaedic principles

The team

Doctors Team:

- Dr. Yubraj Kharel - Senior Consultant Orthopaedic Surgeon
- Dr. Samyukta Acharya- Senior Consultant Anaesthesiologist
- Dr. Rajiv Prasad Shrestha- Registrar Orthopaedic Surgeon
- Dr. Samir Karki- Registrar Orthopaedic Surgeon
- Dr. Anish Gyawali- Registrar Orthopaedic Surgeon
- Dr. Sujit Shrestha- Medical Officer

Nursing team:

- Nursing Supervisor: Suman BC
- Scrubbing team: Tara Ghimire (Senior Staff Nurse)
- Luna Bhattarai (Senior staff Nurse)
- Recovery and Post-op Nurse: Babita Karki (Senior Staff Nurse)
- Anesthesia Assistant: Roshani Maharjan (Senior Staff nurse)
- Pharmacy staff: Anil Shrestha (Senior Pharmacy Assistant)
- Logistic support team:
 - 1) Mr. Ghanshyam Neupane (Senior Office Assistant)
 - 2) Mr. Ramhari Badal (OT Assistant)

Ramechhap hospital doctors, Nurses, x-ray, lab technician and administration Personnel helped the camp in their respective field.

Goals:

- 1. To carry out at least 30 free surgeries
- 2. To carry out at least 1000 OPD checkups and provide all medicines and supplements for free to publicize Nepal Orthopaedic hospital as the best and cost effective center for orthopaedic and trauma management.

Achievements of the camp:

A total of 321 patients were seen in OPD and 39 patients were operated. OPD patient mostly had age related problems.

List of Surgeries	
Fresh Trauma: 2	Excision: 9
Implant removal: 19	Tendon repair ankle: 1
Implant removal failure: 2	Bone graft: 2
Hand surgeries: 3	Steroid Injections: 43

Suggestions

- Some of the equipment and essential lists could be added in future camps:
 - 1. OT light
 - 2. K-wire removal with grip pointed
 - 3. Screw removal set
 - 4. Screw driver
- Active participation from local associates should be encouraged and well counseled about the screening of the patients.
- Proper arrangements to setup OPD a day before camp would help mitigate crowds
- More precise and timely advertisement of the camp is essential.

Short coming of the camp

- Active participation from local doctors and healthcare providers were a major setback of the surgical camp.
- Referred cases could not reach NOH from those remote places due to financial hurdles of patients

Conclusion:

We are pleased to report the tremendous success of our recent surgical camp that successfully met its objectives by offering free medical consultation to 321 patients and performing 39 surgeries, exceeding the

initial goal of 30 surgeries, although number of OPD checkup fell short of targeted 1000. All surgeries were completed smoothly, with excellent outcomes and no complications. In addition to addressing critical surgical needs, such as trauma surgeries, and implant removals, the camp also raised awareness about trauma prevention and orthopaedic care. It further contributed to local capacity building by providing training to healthcare workers. However, the camp faced several logistical challenges, including limited involvement from local healthcare providers, a shortage of manpower, and delays in setting up the operating room. These issues could be addressed through better planning, stronger local coordination, and clearer communication between organizers and local authorities. The camp underscored the significance of such initiatives in remote areas like Ramechhap, where access to specialized healthcare is scarce and encouraged rural populations to visit NOH for quality and reasonable orthopaedic related services in the future. Recommendations for future camps include improved logistics, greater local engagement, and more effective promotion to enhance efficiency and patient reach. To sum up, we extend our heartfelt thanks to Dr. Katrin Hagen and Med-Solution Foundation, Switzerland for their instrumental role in making this camp such a rewarding and impactful experience.

शुभकामना

ने.अ.सं-नेपाल अर्थोपेडिक अस्पतालको २७ औं वार्षिकोत्सवको सुखद उपलक्ष्यमा अस्पताल परिवारलाई हार्दिक मंगलमय शुभकामना व्यक्त गर्न चाहन्छौं । हाडजोर्नी उपचारमा एक अलग्गै पहिचान बनाउन सफल तथा विशिष्टिकृत सेवा दिने यस अस्पतालले निरन्तर सर्वशुलभ, जनमुखि तथा गुणस्तरीय सेवा प्रदान गर्ने अस्पताल बनोस भन्ने अपेक्षा सहित हार्दिक शुभकामना व्यक्त गर्दछौं ।

सक्कम सर्जिकल सप्लायर्स

काठमाण्डौ

शुभकामना

ने.अ.सं-नेपाल अर्थोपेडिक अस्पतालको २७ औं वार्षिकोत्सवको सुखद उपलक्ष्यमा अस्पताल परिवारलाई हार्दिक मंगलमय शुभकामना व्यक्त गर्न चाहन्छौं । हाडजोर्नी उपचारमा एक अलग्गै पहिचान बनाउन सफल तथा विशिष्टिकृत सेवा दिने यस अस्पतालले निरन्तर सर्वशुलभ, जनमुखि तथा गुणस्तरीय सेवा प्रदान गर्ने अस्पताल बनोस भन्ने अपेक्षा सहित हार्दिक शुभकामना व्यक्त गर्दछौं ।

ओरियन फर्मा नेपाल प्रा.लि.

काठमाण्डौ

शुभकामना

ने.अ.सं-नेपाल अर्थोपेडिक अस्पतालको २७ औं वार्षिकोत्सवको सुखद उपलक्ष्यमा अस्पताल परिवारलाई हार्दिक मंगलमय शुभकामना व्यक्त गर्न चाहन्छौं । हाडजोर्नी उपचारमा एक अलग्गै पहिचान बनाउन सफल तथा विशिष्टिकृत सेवा दिने यस अस्पतालले निरन्तर सर्वशुलभ, जनमुखि तथा गुणस्तरीय सेवा प्रदान गर्ने अस्पताल बनोस भन्ने अपेक्षा सहित हार्दिक शुभकामना व्यक्त गर्दछौं ।

त्रिदेव फार्मास्युटिकल्स

काठमाण्डौ

A Report On Free Orthopaedic Surgical Camp

Pashupati Chaulagain Memorial Hospital Charikot, Dolakha
(2081 Jestha 04 TO 2081 Jestha 07) (17th May 2024 – 20th May 2024)

Organized by:

Rotary Club of Kathmandu- West.

NDA- Nepal Orthopaedic Hospital, Narayantar, Jorpati, Kathmandu.

Bhimeshwar Municipality, Charikot, Dolakha.

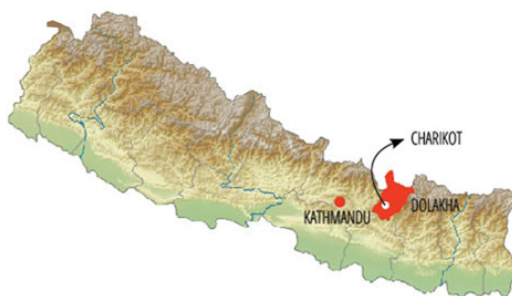
Pashupati Chaulagain Memorial Hospital, Charikot, Dolakha.

Sponsored by:

Med Solution Foundation, Switzerland.

BACKGROUND

Bhimeshwar, formerly known as Charikot is a municipality situated in north-eastern Nepal and is the headquarter of Dolakha district in Bagmati province. The region is bordered by the Sun Koshi river on the west and the Khimti river on the east. Bhimeshwar is formed by merging the former village development committees Charikot, Dolakha town, Makaibari, Mati, Suspaa and Lankuri danda. The town is located at an altitude of 1,554 meters (5101 feet) and it had a population of 40,000 people living in 8639 individual houses.



GOALS:

1. To carry out 30 free orthopaedic and Hand surgeries during 4 days.
2. To carry out atleast 1000 free OPD check ups in 3days and free medicine distribution
3. To publicize Nepal Orthopaedic Hospital as the best and cost effective center for Orthopaedic and trauma care.

Objectives:

1. To give opportunities for the staff of NOH to experience and work in a limited facility centers.
2. To teach local staff about the basic principles n management of Orthopaedic and Trauma cases.
3. To enhance public awareness about the damage prevention measures after trauma thereby preventing deformity and disability

Categories of medicines provided in camp

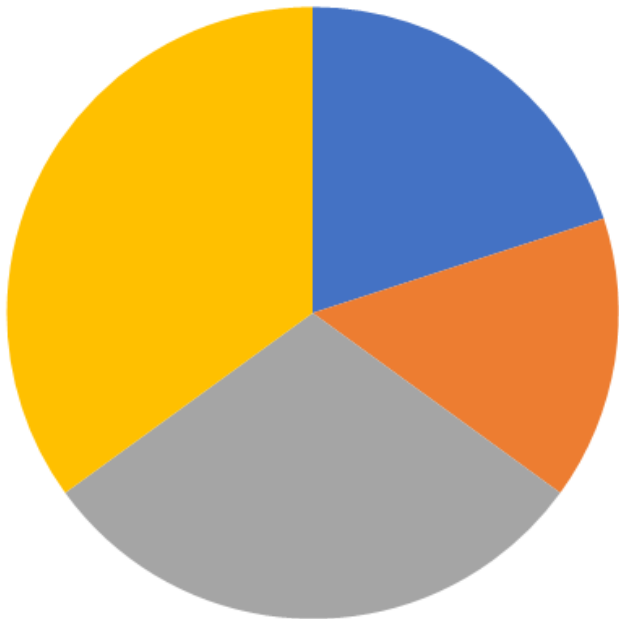
- | | |
|--|----------------------------|
| 1. NSAIDS | 2. Antibiotics |
| 3. Vitamin B complex | 4. Steroids |
| 5. Antigout | 6. Calcium tablets |
| 7. Anti emetics | 8. Anti vertigo |
| 9. Anti hypertensive | 10. Pain killer gel |
| 11. Iron and folic acid supplementations | 12. Anti allergic |
| 13. Laxatives | 14. Proton pump inhibitors |
| 15. Paracetamol | 16. Neurotrophics |

TEAM MEMBERS:

Dr. Samyukta Acharya (Senior consultant anesthesiologist)
Dr. Rachit Sharma (consultant orthopaedic surgeon)
Dr. Anish Gyawali (Registrar orthopaedic surgeon)
Dr. Sumit Lohia (Orthopaedic Surgeon)
Dr. Rama Shankar Gupta (Orthopaedic Surgeon)
Dr. Bijendra Dangol (Orthopaedic Surgeon)
Suman B.C (Nursing Supervisor)

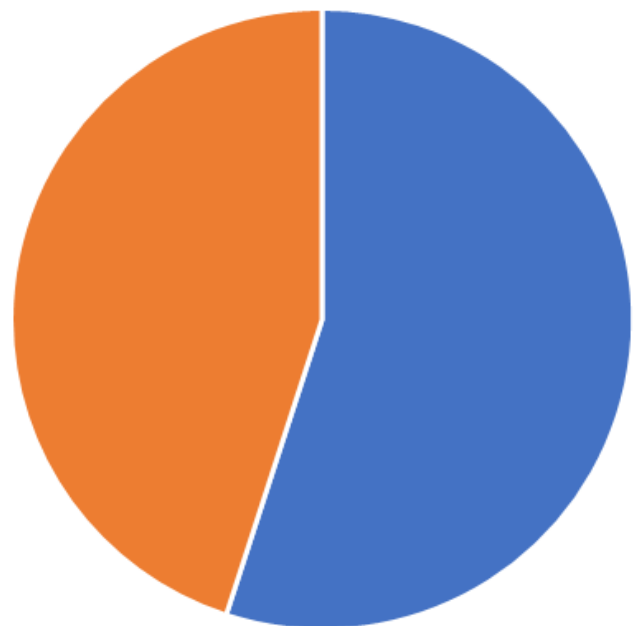
Luna Bhattarai (Senior Staff Nurse)
Babita Karki (Senior Staff Nurse)
Aruna Maharjan (Staff Nurse)
Smriti Adhikari (Staff Nurse)
Bina Aryal (Senior pharmacist)
Sangeeta Thakuri (Logistic Administrator)
Ram Hari Badal (Operation Room Assistant)

Age group



■ 0-15 yrs ■ 16-30 yrs ■ 31-50 yrs ■ >51 yrs

MALE : FEMALE



■ MALE ■ FEMALE ■

LIST OF SURGERIES DONE

Fresh trauma.....	3	Deformity correction.....	3
Implant removal.....	8	Slab/cast application/removal	4
Hand and plastic surgery.....	13	Steroid injections	156
Excisions.....	4		

ACHIEVEMENTS:

1. Total 40 free orthopaedic surgeries performed during 4 days of camp
2. Total of 1197 patients were benefitted with free OPD checkups
3. 156 patient received free steroid injections

SUGGESTIONS:

1. Future camps should be focused in more rural areas so that we will be able to help the poor and needy people more effectively
2. Publicity plays vital role regarding the success of the camp. Mobilization of local partner and volunteers plays a major role.
3. More precise and timely advertisement of the camp is essential

CONCLUSION:

This free orthopaedic surgical camp organized by rotary club of Kathmandu west, NDA- Nepal Orthopaedic Hospital, Bhimeshwor Municipality, Pashupati Chaulagain Memorial Hospital, Charikot, Dolakha and Sponsored by Med Solution Foundation, Switzerland is satisfactorily successful as the number of surgeries performed and the number of OPD patients benefitted are quite good. Most of the cases were hand surgeries, deformity corrections, fresh traumas and implant removals and lastly we would like to thank Rotary club of Kathmandu, west, Bhimeshwor municipality, Pashupati chaulagain memorial hospital and all the doctors, nurses, local volunteers and administratives for making this camp possible and successful.

Thank you!

शुभकामना

ने.अ.सं-नेपाल अर्थोपेडिक अस्पतालको २७ औं वार्षिकोत्सवको सुखद उपलक्ष्यमा अस्पताल परिवारलाई हार्दिक मंगलमय शुभकामना व्यक्त गर्न चाहन्छौं । हाडजोर्नी उपचारमा एक अलग्गै पहिचान बनाउन सफल तथा विशिष्टिकृत सेवा दिने यस अस्पतालले निरन्तर सर्वशुलभ, जनमुखि तथा गुणस्तरीय सेवा प्रदान गर्ने अस्पताल बनोस भन्ने अपेक्षा सहित हार्दिक शुभकामना व्यक्त गर्दछौं ।

कागेश्वरी टेड्र कन्सर्न

काठमाण्डौ

शुभकामना

ने.अ.सं-नेपाल अर्थोपेडिक अस्पतालको २७ औं वार्षिकोत्सवको सुखद उपलक्ष्यमा अस्पताल परिवारलाई हार्दिक मंगलमय शुभकामना व्यक्त गर्न चाहन्छौं । हाडजोर्नी उपचारमा एक अलग्गै पहिचान बनाउन सफल तथा विशिष्टिकृत सेवा दिने यस अस्पतालले निरन्तर सर्वशुलभ, जनमुखि तथा गुणस्तरीय सेवा प्रदान गर्ने अस्पताल बनोस भन्ने अपेक्षा सहित हार्दिक शुभकामना व्यक्त गर्दछौं ।

होपवेल हेल्थकेयर प्रा. लि.

काठमाण्डौ

शुभकामना

ने.अ.सं-नेपाल अर्थोपेडिक अस्पतालको २७ औं वार्षिकोत्सवको सुखद उपलक्ष्यमा अस्पताल परिवारलाई हार्दिक मंगलमय शुभकामना व्यक्त गर्न चाहन्छौं । हाडजोर्नी उपचारमा एक अलग्गै पहिचान बनाउन सफल तथा विशिष्टिकृत सेवा दिने यस अस्पतालले निरन्तर सर्वशुलभ, जनमुखि तथा गुणस्तरीय सेवा प्रदान गर्ने अस्पताल बनोस भन्ने अपेक्षा सहित हार्दिक शुभकामना व्यक्त गर्दछौं ।

स्टार सर्जिकल सप्लायर्स

त्रिपुरेश्वर, काठमाण्डौ

A Report On Free Orthopaedic Surgical camp

Kapilvastu Hospital, Taulihawa, Kapilvastu
25th To 28th November 2024 (10th To 13th Mangsir 2081)



Team members:

- Dr. Katharina Marianne Hagen (Senior Hand Surgeon)
- Dr. Prakash Gyawali (Senior Consultant Orthopaedic Surgeon)
- Dr. Sunil Badgami (Senior Consultant Anesthesiologist)
- Dr. Anil Ghimire (Registrar Orthopaedic Surgeon)
- Dr. Mandeep Karki (Registrar Orthopaedic Surgeon)
- Dr. Anish Gyawali (Registrar Orthopaedic Surgeon)
- Dr. Bijendra Dangol (Orthopaedic Surgeon)
- Mr. Shyam Rupakheti (Chief Administrator)
- Ms. Meena Gurung (Matron)
- Ms. Anita Gurung (Nursing Supervisor)
- Ms. Rolina Karki (Nursing Officer)
- Ms. Merina Karki (Senior Staff Nurse)
- Ms. Sambina Dangol (Senior Staff Nurse)
- Ms. Radhika Khagi (Senior Pharmacist)
- Mr. Salyan Tamang (Operation Room Assistant)



The organizations involved:

Organized by:

- Rotary Club of Kathmandu West
- NDA- Nepal Orthopaedic Hospital, Jorpati
- Kapilvastu District Hospital, Taulihawa, Kapilvastu.
- Kapilvastu Municipality, Taulihawa

Sponsored by :

- Med Solution Foundation, St. Moritz, Switzerland

BACKGROUND:



TAULIHAWA:

Taulihawa is one of the oldest municipality and administrative center of Kapilvastu district in province no. 5 of southern Nepal. Taulihawa is about 25 kilometers from Lumbini, a UNESCO world heritage site and birth place of Gautama Buddha. Taulihawa lies at an altitude of 107 meters above sea level on southern border across from Uttar Pradesh state, India. All of Kapilvastu's VDC can be reached by motor road but 25% of these are not accessible during monsoon season due to heavy rainfall and flood. An airport in Bhairahawa connects the district to Kathmandu by flight of only 35 minutes.

Goals:

- To treat orthopaedic cases at the remote place of Kapilvastu and nearby districts.
- To recognize orthopaedic hospital and its services to remote western development region of Nepal.
- To observe the cultural and geographical identities of Kapilvastu in relation to health politics.

Objectives:

- To give excellent orthopaedic services including OPD, Inpatient and surgeries with free of cost to people of the remote place Kapilvastu and its surrounding districts.
- To give opportunities for the staff of NOH to experience and conduct the total care of orthopaedic as a mobile camp in out reach clinic.
- To advocate Nepal Orthopaedic Hospital nationally and internationally.
- To teach local staff about basic procedures of orthopaedic and trauma cases.
- Provide free surgeries to physically challenged people (Deformity correction, hand n plastic surgeries, contracture release and trauma related surgeries)
- Train the local doctor n health worker basic orthopaedic principles.

Target:

- To conduct OPD patients in 5days (Target 1500 patients)
- To run operating room for 4days (Target 60 surgeries)
- To carry out Local and Intra-articular steroid injections (Target 150 steroid injections)
- To perform 60 surgeries including traumatic, deformity correction and plastic surgeries.



Categories of medicines provided at camp

1. NSAID	8. Anti vertigo	15. Laxative
2. Antibiotics	9. Anti dispersant	16. Proton pump inhibitors
3. Vitamin B-complex	10. Anti hypertensive	17. Paracetamol
4. Steroid	11. Pain killer gel	18. Neurotropics
5. Antigout	12. Iron and folic supplements	19. Muscle relaxants
6. Calcium	13. Anti allergy	
7. Anti emetics	14. Anti histamine	

Surgery Demography:

Surgeries:

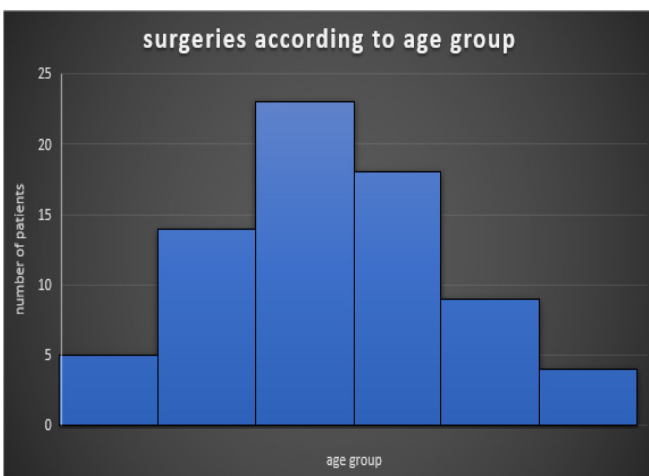
Male	37
Female	27

Age group :

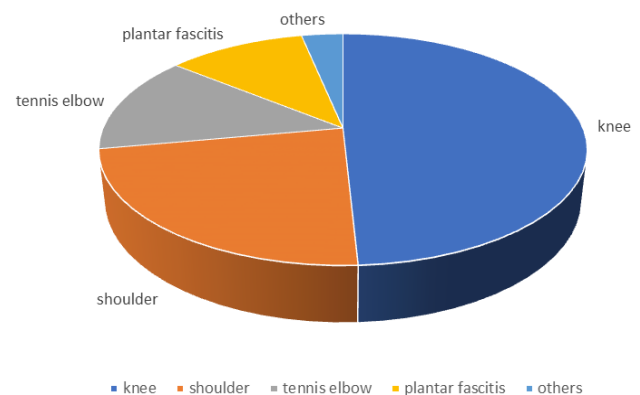
0-15 yrs	9
15-30 yrs	17
30-50 yrs	22
>50 yrs	16

Categories:

Deformity correction	5
Hand and reconstruction	4
Trauma	13
Implant removal	27
Tumor excision	11
Plasters	11
Amputation + flap coverage	1
Debridement + bone drilling	3



Steroid Injections



Suggestions:

- Future camps should be focused in more rural areas so that we will be able to help the poor n needy patients.
- Proper publicity of the camp beforehand plays the vital role in the success of the camp. Hence all the resources must be fully utilized for the publicity of the camp.
- The duration of the camp, OPD check-ups and surgical service must be clearly advertised so that the people visiting from the remote areas can fulfill their requirements.
- The local partners, volunteers and the security individuals are must for the proper functioning of the camp.

Conclusion:

To conclude, though the Kapilvastu municipality is developing in its infrastructure, the people living in this region are facing major problems regarding health service, Sanitation and financial issues. Overall the free orthopaedic surgical camp held in Kapilvastu was successful as our team fulfilled our target and hope to provide free services in future too.

We would like to thank Dr. Katharina Marianne Hagen, Med Solution Foundation, Switzerland, NDA- Nepal Orthopaedic hospital, Rotary Club Kathmandu West, Kapilvastu district hospital and Kapilvastu municipality and Local doctors and medical professionals who are directly or indirectly helped us during this camp to make it effective and successful.

Thank you!

शुभकामना

ने.अ.सं-नेपाल अर्थोपेडिक अस्पतालको २७ औं वार्षिकोत्सवको सुखद उपलक्ष्यमा अस्पताल परिवारलाई हार्दिक मंगलमय शुभकामना व्यक्त गर्न चाहन्छौं । हाडजोर्नी उपचारमा एक अलग्गै पहिचान बनाउन सफल तथा विशिष्टिकृत सेवा दिने यस अस्पतालले निरन्तर सर्वशुलभ, जनमुखि तथा गुणस्तरीय सेवा प्रदान गर्ने अस्पताल बनोस भन्ने अपेक्षा सहित हार्दिक शुभकामना व्यक्त गर्दछौं ।

पामिर इन्टरनेशनल प्रा.लि.

काठमाण्डौ

शुभकामना

ने.अ.सं-नेपाल अर्थोपेडिक अस्पतालको २७ औं वार्षिकोत्सवको सुखद उपलक्ष्यमा अस्पताल परिवारलाई हार्दिक मंगलमय शुभकामना व्यक्त गर्न चाहन्छौं । हाडजोर्नी उपचारमा एक अलग्गै पहिचान बनाउन सफल तथा विशिष्टिकृत सेवा दिने यस अस्पतालले निरन्तर सर्वशुलभ, जनमुखि तथा गुणस्तरीय सेवा प्रदान गर्ने अस्पताल बनोस भन्ने अपेक्षा सहित हार्दिक शुभकामना व्यक्त गर्दछौं ।

मेरिगोल्ड मेडिसिन टेड्रर्स

काठमाण्डौ

शुभकामना

ने.अ.सं-नेपाल अर्थोपेडिक अस्पतालको २७ औं वार्षिकोत्सवको सुखद उपलक्ष्यमा अस्पताल परिवारलाई हार्दिक मंगलमय शुभकामना व्यक्त गर्न चाहन्छौं । हाडजोर्नी उपचारमा एक अलग्गै पहिचान बनाउन सफल तथा विशिष्टिकृत सेवा दिने यस अस्पतालले निरन्तर सर्वशुलभ, जनमुखि तथा गुणस्तरीय सेवा प्रदान गर्ने अस्पताल बनोस भन्ने अपेक्षा सहित हार्दिक शुभकामना व्यक्त गर्दछौं ।

स्वयम्भु फार्मास्युटिकल

काठमाण्डौ

MAJOR CHARITY PROFILE

NEPAL ORTHOPAEDIC HOSPITAL

Diagnosis: Fracture mid shaft of femur left.

Surgery: Total hip arthroplasty

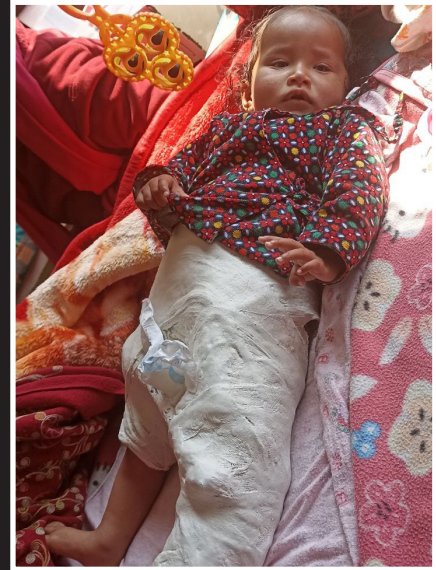Charity: 8590 out of Rs. 8590

Conservative management with gallows traction which later changed to hip spica cast (1&1/2)

BACKGROUND:

Miss Menuka Dargi, a 6-month-old female infant and temporary resident of Suntakhan, Kathmandu, sustained an injury to her left femur following a fall from a bed. She was brought to our hospital with complaints of pain in the left thigh.

Her parents, both laborers by profession, belong to a financially disadvantaged family of seven members, including five children. Given their economic condition, the Nepal Orthopaedic Hospital (NOH) provided full charitable support, including free medication and meals throughout the hospital stay. The patient was discharged in stable condition, and the family expressed gratitude for the support received.



NAME: Menuka Dargi

Age/Sex: 6 months/Female

ADDRESS: Suntakhan

MAJOR CHARITY PROFILE

NEPAL ORTHOPAEDIC HOSPITAL

Diagnosis: Infected non-union distal tibia/fibula left leg.

Surgery: Illizarov ring fixator left leg under SAB on 2023/03/27; bone squaring distal tibia + proximal tibia corticotomy under SAB on 2023/04/10.

Charity: Rs. 50500 out of Rs. 50500

BACKGROUND:

Mrs. Geeta Gharti Magar, a 27-year-old female from Rolpa — a remote area in the mid-western region of Nepal — presented to our hospital with complaints of pain in the left leg, which had persisted for 1.5 years following a fall from standing height.

She had undergone surgery at another center 10 months prior. However, postoperatively, she developed an infection leading to implant exposure. Due to her poor economic condition — relying solely on subsistence farming — and a history of seizures that limits her ability to work, she was unable to afford further treatment.

Considering her circumstances, the National Orthopaedic Hospital (NOH) provided full charitable support throughout her hospital stay, including medical care and other associated costs. She was discharged in stable condition, and we extend our best wishes for her speedy recovery.



NAME: Geeta Gharti Magar

Age/Sex: 27 yrs/Female

ADDRESS: Rolpa

MAJOR CHARITY PROFILE

NEPAL ORTHOPAEDIC HOSPITAL

Diagnosis: Fracture tibia plateau (SCH-VI) with cut injury left thigh.
Surgery: ORIF with dual plate + ABG under SAB Epidural on 2024/01/11.
Charity: Rs. 22000 out of Rs. 312055

BACKGROUND:

Mr. Anuj Hamal, a 25-year-old male from Jorpati, Kathmandu, presented to our hospital with complaints of pain and swelling over the left knee and proximal leg, along with a laceration over the thigh sustained in a road traffic accident (RTA) one day prior to presentation. He underwent the necessary surgical procedure at our hospital. Due to his poor economic background and the fact that he is the sole breadwinner of the family, working as a daily wage laborer, he was unable to afford the cost of treatment. The accident had rendered him temporarily unable to support his family. Recognizing his difficult circumstances, Nepal Orthopaedic Hospital (NOH) extended significant charitable support to ensure he received the required medical care. He was managed successfully and discharged with appropriate follow-up advice.



NAME: Anuj Hamal
Age/Sex: 25yrs/M
ADDRESS: Jorpati

Charity No. : 3
I P No: 23/1967

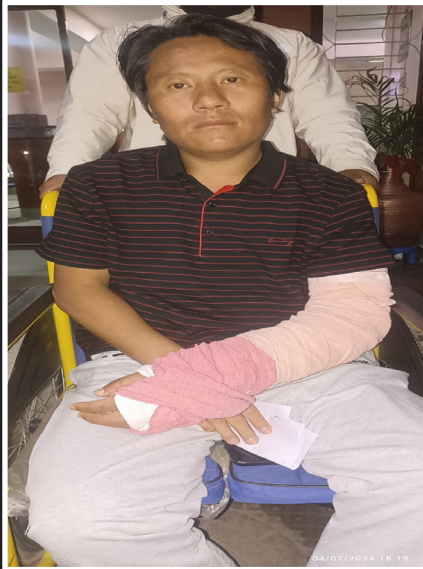MAJOR CHARITY PROFILE

NEPAL ORTHOPAEDIC HOSPITAL

Diagnosis: Olecranon fracture left with comminuted distal radius fracture with comminuted reverse oblique IT fracture left..
Surgery: ORIF with PFN for IT fracture, ORIF with buttress plate + K-wires for distal radius fracture and ORIF with TBW for olecranon fracture on 2024/01/21 under SAB + BPB.
Charity: RS 46990 out of 146990

BACKGROUND:

Mr. Barna Barash Rai, a 26-year-old male and temporary resident of Jorpati, Kathmandu, was admitted to our hospital after sustaining severe injuries from a fall from a three-story building. He underwent the required surgical intervention and remained hospitalized for 17 days. Due to his financial hardship—being the sole income earner in a family of seven and working as a daily wage laborer—he was unable to afford the full cost of treatment. In light of his situation, Nepal Orthopaedic Hospital (NOH) provided substantial charitable support to cover his medical expenses. He is currently in the recovery phase and continues to receive follow-up care.



NAME: Barna Barash Rai
Age/Sex: 26 years/Male
ADDRESS: Jorpati

Charity No. : 4
I P No: 24/84



Charity No. : 5

I P No: 24/256

MAJOR CHARITY PROFILE

NEPAL ORTHOPAEDIC HOSPITAL

Diagnosis: Fracture distal tibia right (Gustilo-II).

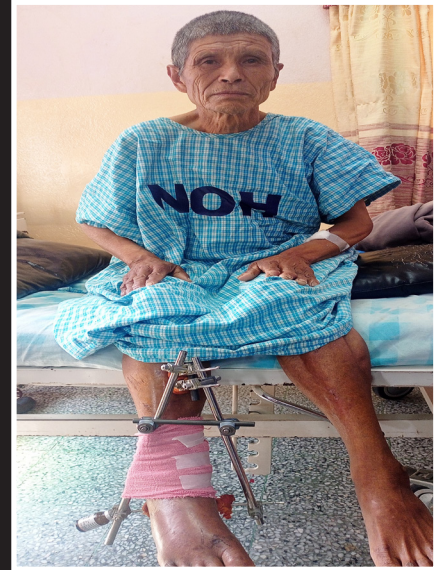Surgery: Delta frame application under SAB on 2024/02/19.

Charity: Rs.68240 out of RS.137780.

BACKGROUND:

Mr. Gopal Jirel, a 57-year-old male and permanent resident of Jiri, Dolakha, presented to our hospital with complaints of pain over the right distal leg after being struck by a block of wood on the day of admission. Upon evaluation, he was diagnosed with a right distal tibia fracture (Gustilo Type II), for which a delta frame application was performed under spinal anesthesia (SAB).

As a dedicated farmer supporting his family through hard work in the fields, Mr. Gopal faced significant financial challenges in affording the necessary treatment. Recognizing his situation, Nepal Orthopaedic Hospital (NOH) provided charitable assistance to cover his medical care. He was managed successfully and discharged in stable condition.



NAME: Gopal Jirel

Age/Sex: 57 years/Male

ADDRESS: Jiri

MAJOR CHARITY PROFILE

NEPAL ORTHOPAEDIC HOSPITAL

Charity No. : 6

I P No: 24/275

Diagnosis: Comminuted fracture distal radius and ulna left.

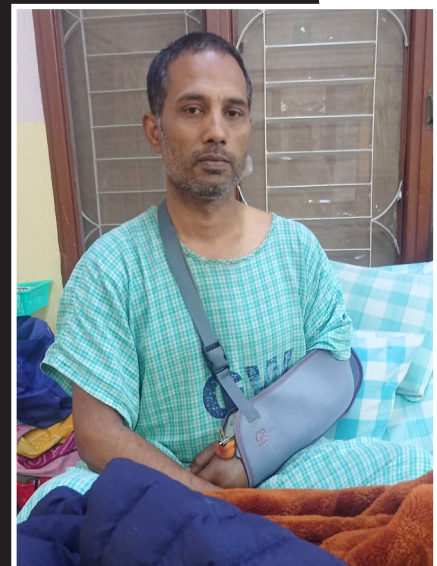Surgery: UMEX application under BPB on 2024/02/22.

Charity: RS.23490 out of RS.61490.

BACKGROUND:

Mr. Sachit Shah, a 46-year-old male and permanent resident of Morang, presented to our hospital with complaints of pain, swelling, and inability to move the left wrist, following a fall injury sustained on the day of admission.

As the sole breadwinner for a family of five, Mr. Shah worked tirelessly as a laborer to support his family. However, the financial burden of treatment was beyond his means. Recognizing his difficult circumstances, Nepal Orthopaedic Hospital (NOH) provided substantial charitable assistance to ensure he received the necessary medical care.



NAME: Sachit Shah

Age/Sex: 46 years/Male

ADDRESS: Urlabari



MAJOR CHARITY PROFILE

NEPAL ORTHOPAEDIC HOSPITAL

Diagnosis: Distal femur fracture right with segmental both bone fracture right leg (GA II) with fracture lateral malleolus right.

Surgery: Wound debridement + external fixator application+ proximal tibial skeletal traction under SAB on 2024/04/23 and Wound debridement+ stay suturing under SAB on 2024/05/14.

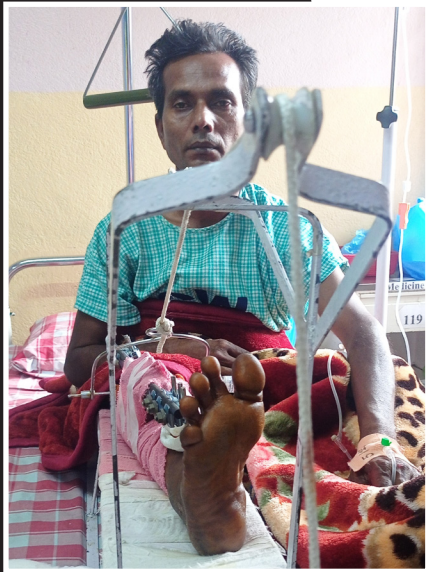Charity: RS.112005 out of RS.211570.

BACKGROUND:

Mr. Sheikh Basir, a 40-year-old male from Rautahat, a district in Madhesh Province, presented to our hospital with complaints of pain and swelling over the right thigh and leg, along with pain in the left shoulder, following a road traffic accident (RTA) one day prior to admission.

He underwent the necessary surgical intervention at our hospital. As the sole provider for a family of 11, Mr. Basir has worked tirelessly to support his household, despite facing significant financial hardship. Coming from a very poor background, the cost of medical treatment was beyond his means.

In light of his circumstances, Nepal Orthopaedic Hospital (NOH) extended substantial charitable support to ensure he received the care he required. He is currently on the path to recovery and continues to attend regular follow-up visits.



NAME: Sheikh Basir

Age/Sex: 40 years/Male

ADDRESS: Rautahat

Charity No. : 7

I P No: 24/565

MAJOR CHARITY PROFILE

NEPAL ORTHOPAEDIC HOSPITAL

Diagnosis: Fracture shaft of tibia right(2 months old)

Surgery: ORIF with SIGN Nail + Autologous bone graft

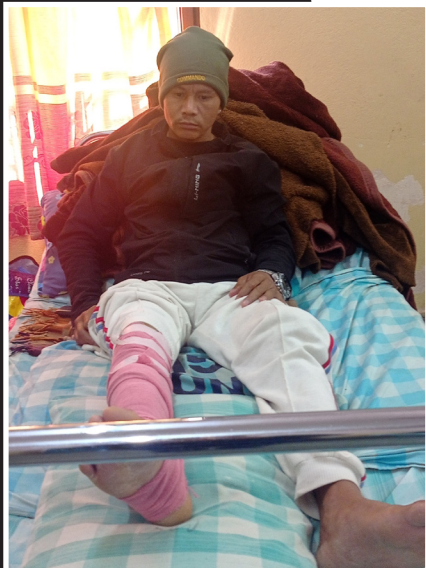Charity: Rs. 52100 out of Rs. 62100.

BACKGROUND:

Mr. Suman Tamang, a 37-year-old male from Bhaktapur, presented to our center with complaints of pain, deformity, and inability to bear weight on the right leg following a fall injury (road traffic accident) that occurred two months prior to admission.

Despite sustaining the fracture two months earlier, he was unable to seek treatment due to financial constraints. As the sole provider for a family of four, Mr. Tamang has worked diligently to support his household while facing ongoing economic hardship.

He underwent the indicated surgical procedure at our hospital. In light of his financial situation, Nepal Orthopaedic Hospital (NOH) provided substantial charitable support to ensure he received the necessary treatment. He is now recovering and under regular follow-up care.



NAME: Suman Tamang

Age/Sex: 37 years/Male

ADDRESS: Bhaktapur

Charity No. : 8

I P No: 24/29



Charity No. : 9

I P No: 24/238

MAJOR CHARITY PROFILE

NEPAL ORTHOPAEDIC HOSPITAL

Diagnosis: Fracture NOF left.**Surgery:** Hemiarthroplasty with AM prosthesis on 2024/02/23 under SAB.**Charity:** Rs. 39600 out of Rs. 79600

BACKGROUND:

Mr. Tenji Sherpa, a 74-year-old senior citizen from Jiri, was admitted to our hospital with severe pain following a fall from height that occurred seven days prior to presentation. After thorough evaluation, he was diagnosed with a condition requiring hemiarthroplasty with an Austin Moore (AM) prosthesis.

As a respected elder of a large family of 15, Mr. Sherpa has spent his life supporting his loved ones. However, due to limited financial resources, the family was unable to afford the cost of the necessary surgical intervention.

Recognizing their circumstances, Nepal Orthopaedic Hospital (NOH) provided significant charitable assistance to ensure that Mr. Sherpa received the appropriate medical care. He is now recovering and under regular follow-up.

**NAME:** Tenji Sherpa

Age/Sex: 74 years/Male

ADDRESS: Jiri

MAJOR CHARITY PROFILE

NEPAL ORTHOPAEDIC HOSPITAL

Charity No. : 10

I P No: 24/459

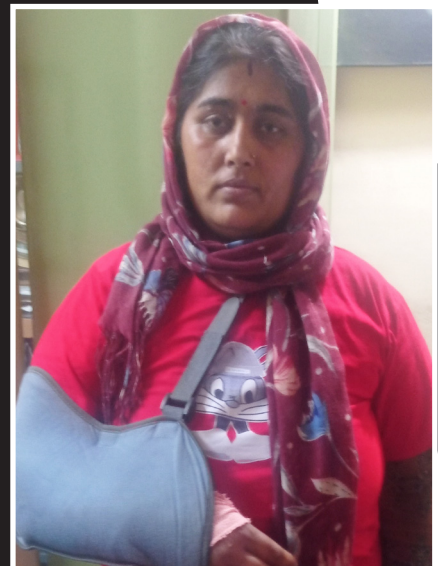Diagnosis: Radius/Ulna fracture right forearm**Surgery:** ORIF with SF-DCP with BPB**Charity:** Rs. 55145 out of Rs. 61820

BACKGROUND:

Ms. Bimala Bhattarai, a 33-year-old female from a remote area of Okhaldhunga, was admitted to our hospital following a fall injury sustained while working in the field. She presented with pain and swelling over the right forearm.

Upon evaluation, she was diagnosed with a fracture of both bones in the right forearm, requiring open reduction and internal fixation (ORIF) with a small fragment dynamic compression plate (SF-DCP) under brachial plexus block (BPB).

Living in a remote area with limited access to healthcare and relying on farming as the primary source of income for her family of six, Ms. Bhattarai faced significant financial challenges in managing her treatment. Understanding her situation, Nepal Orthopaedic Hospital (NOH) provided substantial charitable assistance to ensure she received the necessary care.

**NAME:** Bimala Bhattarai

Age/Sex: 33 years/Female

ADDRESS: Okhaldhunga



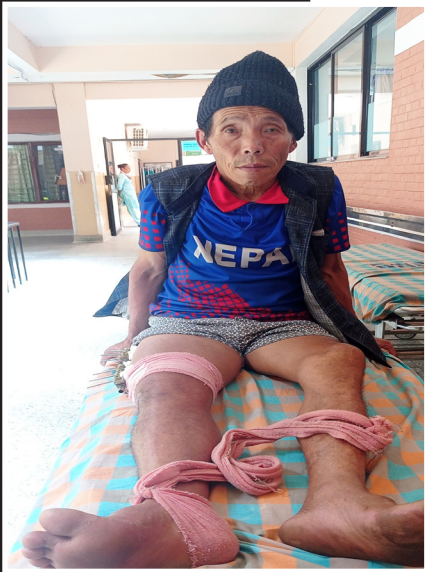MAJOR CHARITY PROFILE

NEPAL ORTHOPAEDIC HOSPITAL

Diagnosis: Fracture proximal SOF right (Gustilo-IIIa) (2024-03-25)
Nonunion ST# Right Femur with EX-FIX in situ (2024-06-3)
Surgery: Wound debridement + External fixation Application under SAB on 2024/03/26 and wound debridement + closure under SAB on 2024/04/21.
EX-FIX removal + wound debridement and secondary closure + MUA under SAB on 2024-06-4
ORIF with SIGN Nail + ABG under SAB on 2024-06-23
Charity: Rs. 60000 out of Rs. 208565

BACKGROUND:

Mr. Bhim Bahadur Sunuwar, a 58-year-old male from Ramechhap, was diagnosed with a proximal shaft of femur (SOF) fracture on the right side, classified as Gustilo Type IIIa, following a severe fall from a tractor. He was advised to undergo surgery to repair the fracture. His family earns their income through farming and was able to contribute NPR 148,565 towards the total treatment cost of NPR 208,565. The hospital kindly waived the remaining balance as charitable support to ensure he received the necessary treatment.



NAME: Bhim Bahadur Sunuwar

Age/Sex: 58 years/Male
ADDRESS: Ramechhap

Charity No. : 11
I P No: 24/436

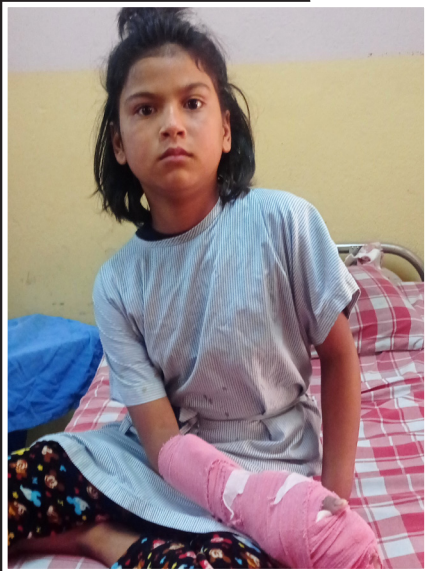MAJOR CHARITY PROFILE

NEPAL ORTHOPAEDIC HOSPITAL

Diagnosis: Infected Cut injury with tendon injury right hand
Surgery: Debridement + tendon repair and stay suturing
Charity: Rs. 11400 out of Rs. 11400

BACKGROUND:

Miss Nirjala Karki, an 11-year-old female from a remote area in Dolakha, presented to our center following a fall injury that resulted in a deep cut on her right hand caused by a sharp object. She was initially taken to another facility where primary management was performed. Due to her family's poor economic condition—her mother works as a laborer and struggles to meet even basic needs, while her father has been disabled since birth—they were unable to afford the costs of further treatment. Recognizing their dire situation, Nepal Orthopaedic Hospital (NOH) provided full charitable support to cover her treatment expenses, ensuring that Miss Karki received the necessary medical care.



NAME: Nirjala Karki

Age/Sex: 11 Years/Male
ADDRESS: Dolakha

Charity No. : 12
I P No: 24/678



Charity No. : 13

I P No: 24/639

MAJOR CHARITY PROFILE

NEPAL ORTHOPAEDIC HOSPITAL

Diagnosis: I/T fracture with ST extension right femur with seizure disorder

Surgery: ORIF with (9 hole) proximal femoral locking plate under SAB on 2024/05/08.

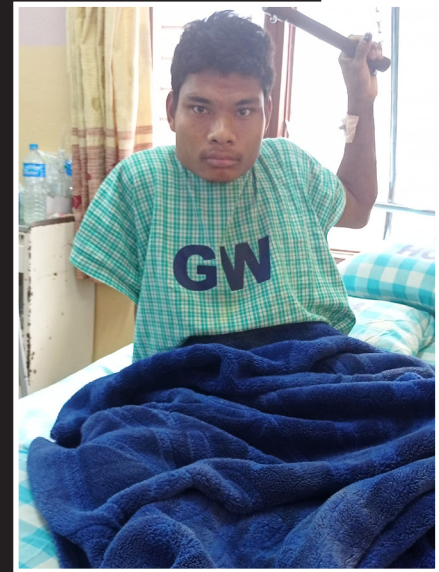Charity: Rs. 104975 + Rs. 34643 of medicine out of Rs. 104975

BACKGROUND:

Mr. Bharat Praja, a 24-year-old male from Makawanpur, presented to our center with complaints of pain over the right thigh following a fall from approximately 50 meters, occurring three days prior to admission.

As the sole breadwinner for his family of seven and a member of the vulnerable Chepang community, Mr. Praja relies on farming for income and faced significant financial challenges in affording his treatment.

Recognizing his difficult circumstances, Nepal Orthopaedic Hospital (NOH) provided full charitable support, covering all medical expenses including medications, to ensure he received the necessary care.

**NAME: Bharat Praja**

Age/Sex: 24 years/Male

ADDRESS: Makawanpur

MAJOR CHARITY PROFILE

NEPAL ORTHOPAEDIC HOSPITAL

Charity No. : 14

I P No: 24/1783

Diagnosis: Right supracondylar humerus fracture

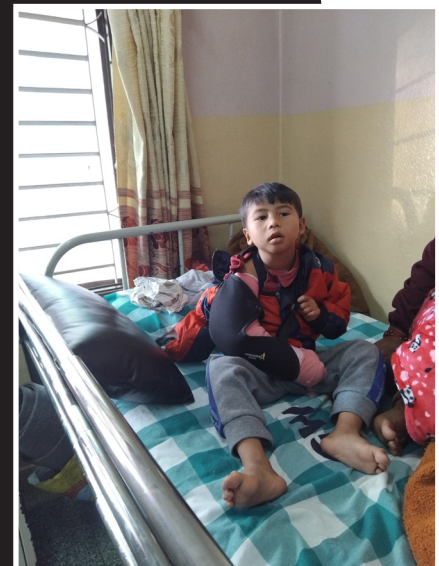Surgery: ORIF with K-wire.

Charity: Rs. 39130 out of Rs. 39130

BACKGROUND:

Mr. Prabesh BK, a 4-year-old male from Nuwakot, was brought to our center following a fall injury. His father works as a laborer, performing minor tasks such as cutting iron and metal. Both of Prabesh's parents are deaf, and both he and his sibling have been diagnosed with autism.

Given the family's challenging situation and limited financial resources, Nepal Orthopaedic Hospital (NOH) provided full charitable support to cover all medical expenses, ensuring that Prabesh received the necessary care.

**NAME: Prabesh BK**

Age/Sex: 4 Years/Male

ADDRESS: Nuwakot



MAJOR CHARITY PROFILE

NEPAL ORTHOPAEDIC HOSPITAL

Diagnosis: Post traumatic stiffness left elbow.

Surgery: Arthrolysis under BPB.

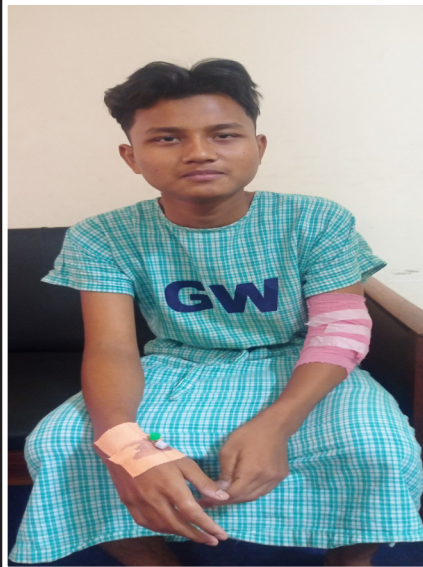Charity: Rs. 30000 out of Rs. 32800

BACKGROUND:

Mr. Bisesh Rajbanshi, a 17-year-old male from Jhapa, presented to our center with complaints of pain and stiffness in the left elbow, resulting from a fall from standing height three years prior.

Coming from a low-income family, he was unable to afford the cost of treatment. Therefore, Nepal Orthopaedic Hospital (NOH) provided charitable support to ensure he received the proper care and treatment needed.

Charity No. : 15
I P No: 24/727



NAME: Bisesh Rajbanshi
Age/Sex: 17 years/Male
ADDRESS: Jhapa

MAJOR CHARITY PROFILE

NEPAL ORTHOPAEDIC HOSPITAL

Diagnosis: Trimalleolar fracture dislocation right ankle.

Surgery: ORIF with 1/3rd tubular plate and ORIF with K-wires with syndesmotic screw under SAB on 2024/02/23.

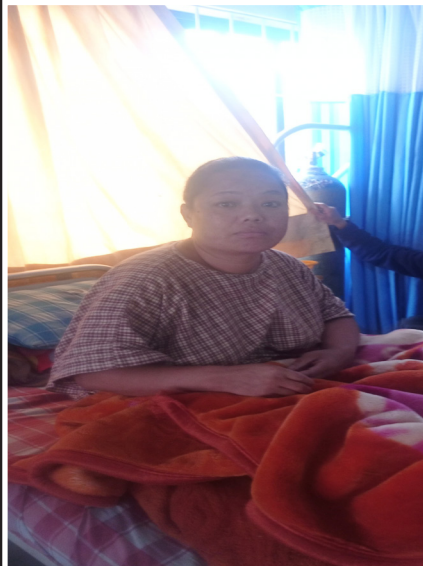Charity: Rs. 32800 out of Rs. 87435

BACKGROUND:

Ms. Sapana Lama, a 39-year-old female from Kavre, presented to our hospital with pain, swelling, and an open wound over the ankle joint following a fall injury sustained under the influence of alcohol 20 days prior to admission.

She has no source of income and suffers from a mental health disorder. Additionally, she lives alone following a divorce. Due to her challenging social circumstances and financial constraints, Nepal Orthopaedic Hospital (NOH) provided partial charitable support to ensure she received the necessary medical care.

Charity No. : 16
I P No: 24/160



NAME: Sapana Lama
Age/Sex: 39 Years/Female
ADDRESS: Kavre



Charity No. : 17

I P No: 24/618

MAJOR CHARITY PROFILE

NEPAL ORTHOPAEDIC HOSPITAL

Diagnosis: Left tibial plateau fracture (SCH-VI) with Syphilis.

Surgery: ORIF with Dual plating under regional block 2024/05/05.

Charity: Rs. 40365 out of Rs. 85755

BACKGROUND:

Manisha Thapa, a 46-year-old female from Narayantar, presented to our center with complaints of pain in the left knee following a fall from stairs one day prior to admission.

Her family's primary source of income is labor work, and they were unable to afford the full cost of treatment. Given their financial situation, Nepal Orthopaedic Hospital (NOH) provided charitable assistance to ensure she received the necessary medical care.

**NAME: Manisha Thapa**

Age/Sex: 46 years/Female

ADDRESS: Narayantar

MAJOR CHARITY PROFILE

NEPAL ORTHOPAEDIC HOSPITAL

Diagnosis: Infected non-union fracture of distal 3rd tibia/fibula left with implant in situ.

Surgery: Debridement +HWR under SAB on 2024/08/24 and Ilizarov ring fixator application under SAB on 2024/09/16.

Charity: Rs.62345 out of Rs.171505

BACKGROUND:

Mr. Janak Chaudhary, a 29-year-old male from Dang, presented to our hospital with an injury to his right leg sustained in a road traffic accident (RTA) 10 months prior. He had previously undergone surgery involving minimally invasive plate osteosynthesis (MIPPO) with distal tibial locking plate, a 1/3 tubular plate, and K-wire fixation at another center. However, his condition worsened, prompting him to seek further intervention and management at our hospital.

As the primary provider for his family of five, Mr. Chaudhary's agricultural income was insufficient to cover the treatment costs. His family was able to contribute NPR 109,160 toward the expenses, while the hospital waived the remaining balance as charitable support. Additionally, the hospital provided the surgical implant free of charge as part of the charity care.

**NAME: Janak Chaudhary**

Age/Sex: 29 years/Male

ADDRESS: Dang



MAJOR CHARITY PROFILE

NEPAL ORTHOPAEDIC HOSPITAL

Diagnosis: Open fracture (GA-II) distal femur fracture with foreign body in situ.

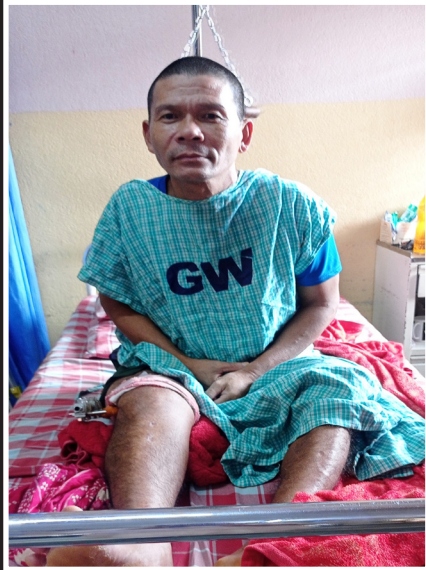Surgery: Debridement + external fixator + removal of foreign body on 2024/05/22.

Charity: Rs.36615 out of Rs.196020

BACKGROUND:

Mr. Tasbir Ghising, a 49-year-old male from a remote area of Makwanpur District, presented to our hospital with pain, swelling, and a wound over the right distal thigh following a blast injury and impact to the right knee. Upon examination, he was diagnosed with an open fracture distal femur with foreign body.

He underwent the required surgical intervention at our hospital. As the primary provider for his family, the financial burden of treatment was beyond their means. Recognizing his difficult situation, Nepal Orthopaedic Hospital (NOH) provided substantial charitable assistance to cover his medical expenses. The hospital also supplied the implant required for his surgery as part of the charity support.



NAME: Tasbir Ghising

Age/Sex: 49 years/Male

ADDRESS: Makwanpur

Charity No. : 19

I P No: 24/763

MAJOR CHARITY PROFILE

NEPAL ORTHOPAEDIC HOSPITAL

Diagnosis: Status post fracture medial epicondyle left humerus with K- wires in situ.

Surgery: Re-Fixation with K-Wires and partially threaded cancellous screw on 2024/09/05.

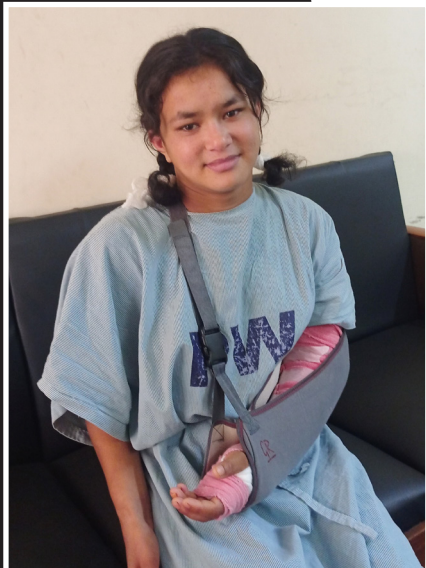Charity: Rs.22670 out of Rs.22670

BACKGROUND:

Miss Hima Khatri, a 15-year-old child from Okhaldhunga, was a known case of medial epicondyle fracture of the left humerus. She underwent open reduction and internal fixation (ORIF) with K-wires at our hospital two weeks ago and returned for a scheduled follow-up.

During evaluation, her follow-up X-ray revealed displacement of the fracture fragment. Hima's mother, a single parent responsible for four children, supports the entire family by working as a laborer in others' fields.

Recognizing the family's financial hardship, Nepal Orthopaedic Hospital (NOH) provided full charitable support, including medication, to ensure Hima received the necessary medical care.



NAME: Hima Khatri

Age/Sex: 15 years/female

ADDRESS: Okhaldhunga

Charity No. : 20

I P No: 24/1238



MAJOR CHARITY PROFILE

NEPAL ORTHOPAEDIC HOSPITAL

Diagnosis: Distal ulna shaft fracture left.

Surgery: Open Osteoclasia and fixation with SF-DCP under BPB done on 2024/12/15.

Charity: Rs.29790 out of Rs.63790

BACKGROUND:

Mrs. Sancha Maya Rai, a 45-year-old female from a remote region of Khotang, sustained an injury after falling down the stairs approximately two months prior to her presentation. She initially received care at a nearby medical center where a cast was applied. However, upon further radiological evaluation at our hospital, it was determined that surgical intervention was required.

She was admitted and successfully managed with surgery. As the sole caregiver for her three children-with no financial or emotional support from her husband-Mrs. Rai relies entirely on subsistence farming for the family's livelihood, leaving her in a financially vulnerable situation. Her relatives managed to gather part of the required treatment cost, and the remaining expenses were supported through the Nepal Orthopaedic Hospital (NOH) charity fund, ensuring she received the comprehensive care she needed.

**NAME: Sancha Maya Rai**

Age/Sex: 45 years/Female

ADDRESS: Khotang

MAJOR CHARITY PROFILE

NEPAL ORTHOPAEDIC HOSPITAL

Diagnosis: Fracture shaft of right femur.

Surgery: CRIF with TENS under SAB on 2024/11/06.

Charity: Rs.20880 out of Rs.65880

BACKGROUND:

Master Pabin Acharya, a 7-year-old child from a remote area of Sindhupalchowk, presented to the Emergency Room with complaints of pain and swelling over the right thigh. Upon evaluation, he was diagnosed with a fracture of the shaft of the right femur, requiring urgent surgical intervention.

He comes from a family of three with no stable source of income. Due to their financial hardship, his parents were unable to afford the necessary treatment.

Recognizing their situation, Nepal Orthopaedic Hospital (NOH) provided charitable support to cover a significant portion of the treatment costs. Pabin was successfully managed and discharged after 10 days of hospital stay.

**NAME: Pabin Acharya**

Age/Sex: 7 years/Male

ADDRESS: Sindhupalchowk



MAJOR CHARITY PROFILE

NEPAL ORTHOPAEDIC HOSPITAL

Diagnosis: Both bone fracture left leg.

Surgery: CRIF with SIGN nail under SAB on 2024/06/09.

Charity: Rs.21450 out of Rs.63850

BACKGROUND:

Mr. Ganesh Sarki, a 52-year-old male and temporary resident of Aarubari, Kathmandu, presented to the Emergency Department of our hospital with complaints of pain in the left leg following a fall from height. He required immediate surgical intervention.

He comes from a large family with no stable source of income and has been facing significant financial hardship. While his family was able to manage a portion of the treatment cost, the remaining expenses were waived by Nepal Orthopaedic Hospital (NOH) as charitable support.

After a 10-day hospital stay, Mr. Sarki was successfully discharged and expressed his heartfelt gratitude to the NOH team for the care and support provided.



NAME: Ganesh Sarki

Age/Sex: 52 years/Male

ADDRESS: Aarubari

शुभकामना

ने.अ.सं-नेपाल अर्थोपेडिक अस्पतालको २७ औं वार्षिकोत्सवको सुखद उपलक्ष्यमा अस्पताल परिवारलाई हार्दिक मंगलमय शुभकामना व्यक्त गर्न चाहन्छौं । हाडजोर्नी उपचारमा एक अलग्गै पहिचान बनाउन सफल तथा विशिष्टिकृत सेवा दिने यस अस्पतालले निरन्तर सर्वशुलभ, जनमुखि तथा गुणस्तरीय सेवा प्रदान गर्ने अस्पताल बनोस भन्ने अपेक्षा सहित हार्दिक शुभकामना व्यक्त गर्दछौं ।

फरमेड प्रा.लि.

काठमाण्डौ

शुभकामना

ने.अ.सं-नेपाल अर्थोपेडिक अस्पतालको २७ औं वार्षिकोत्सवको सुखद उपलक्ष्यमा अस्पताल परिवारलाई हार्दिक मंगलमय शुभकामना व्यक्त गर्न चाहन्छौं । हाडजोर्नी उपचारमा एक अलग्गै पहिचान बनाउन सफल तथा विशिष्टिकृत सेवा दिने यस अस्पतालले निरन्तर सर्वशुलभ, जनमुखि तथा गुणस्तरीय सेवा प्रदान गर्ने अस्पताल बनोस भन्ने अपेक्षा सहित हार्दिक शुभकामना व्यक्त गर्दछौं ।

बजरंग इन्टरप्राइजेज

काठमाण्डौ

शुभकामना

ने.अ.सं-नेपाल अर्थोपेडिक अस्पतालको २७ औं वार्षिकोत्सवको सुखद उपलक्ष्यमा अस्पताल परिवारलाई हार्दिक मंगलमय शुभकामना व्यक्त गर्न चाहन्छौं । हाडजोर्नी उपचारमा एक अलग्गै पहिचान बनाउन सफल तथा विशिष्टिकृत सेवा दिने यस अस्पतालले निरन्तर सर्वशुलभ, जनमुखि तथा गुणस्तरीय सेवा प्रदान गर्ने अस्पताल बनोस भन्ने अपेक्षा सहित हार्दिक शुभकामना व्यक्त गर्दछौं ।

सुविधा टेडर्स

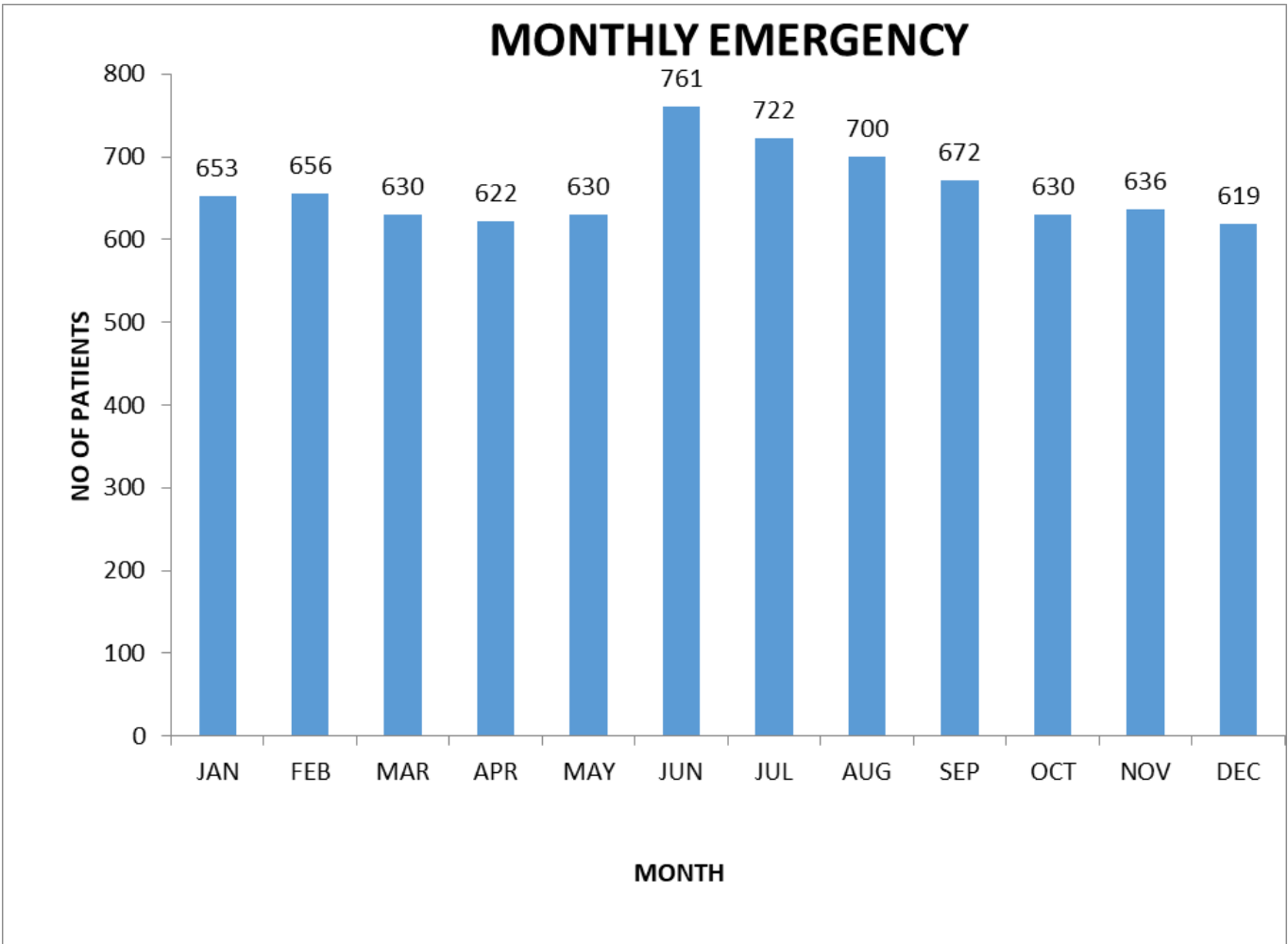
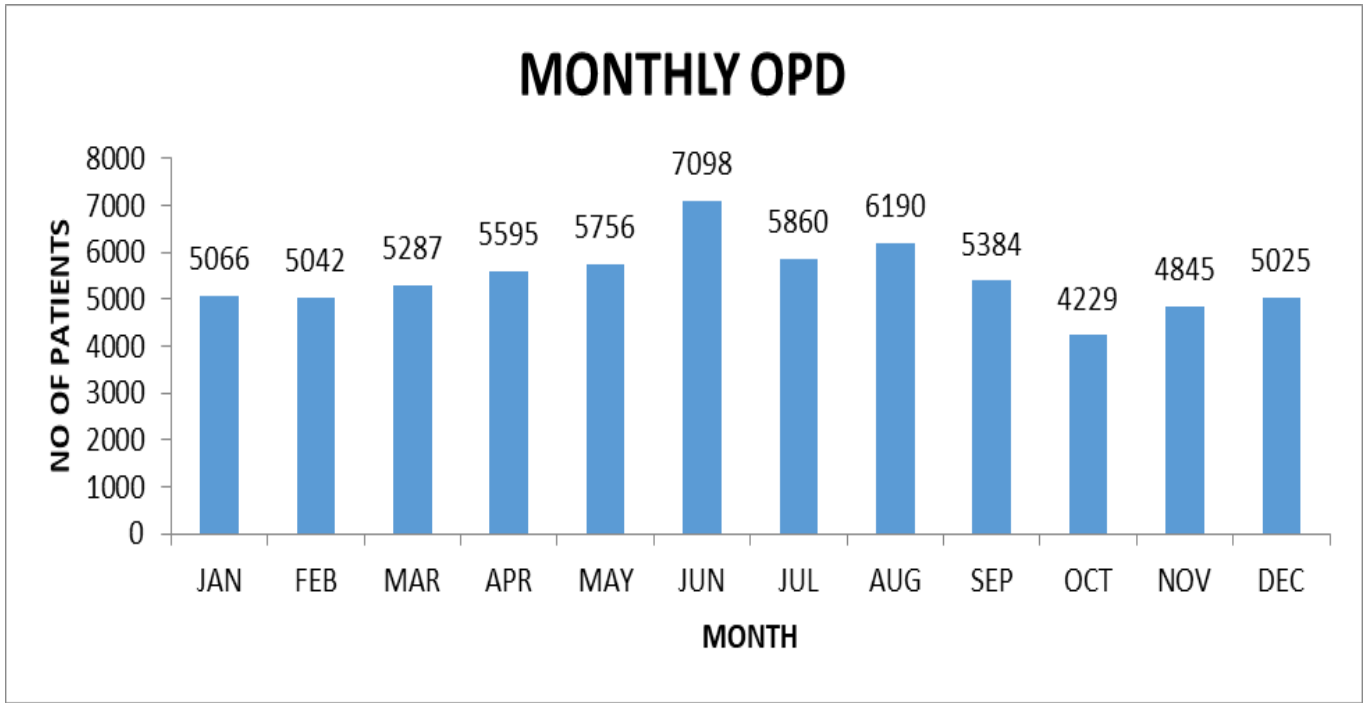
काठमाण्डौ

शुभकामना

ने.अ.सं-नेपाल अर्थोपेडिक अस्पतालको २७ औं वार्षिकोत्सवको सुखद उपलक्ष्यमा अस्पताल परिवारलाई हार्दिक मंगलमय शुभकामना व्यक्त गर्न चाहन्छौं । हाडजोर्नी उपचारमा एक अलग्गै पहिचान बनाउन सफल तथा विशिष्टिकृत सेवा दिने यस अस्पतालले निरन्तर सर्वशुलभ, जनमुखि तथा गुणस्तरीय सेवा प्रदान गर्ने अस्पताल बनोस भन्ने अपेक्षा सहित हार्दिक शुभकामना व्यक्त गर्दछौं ।

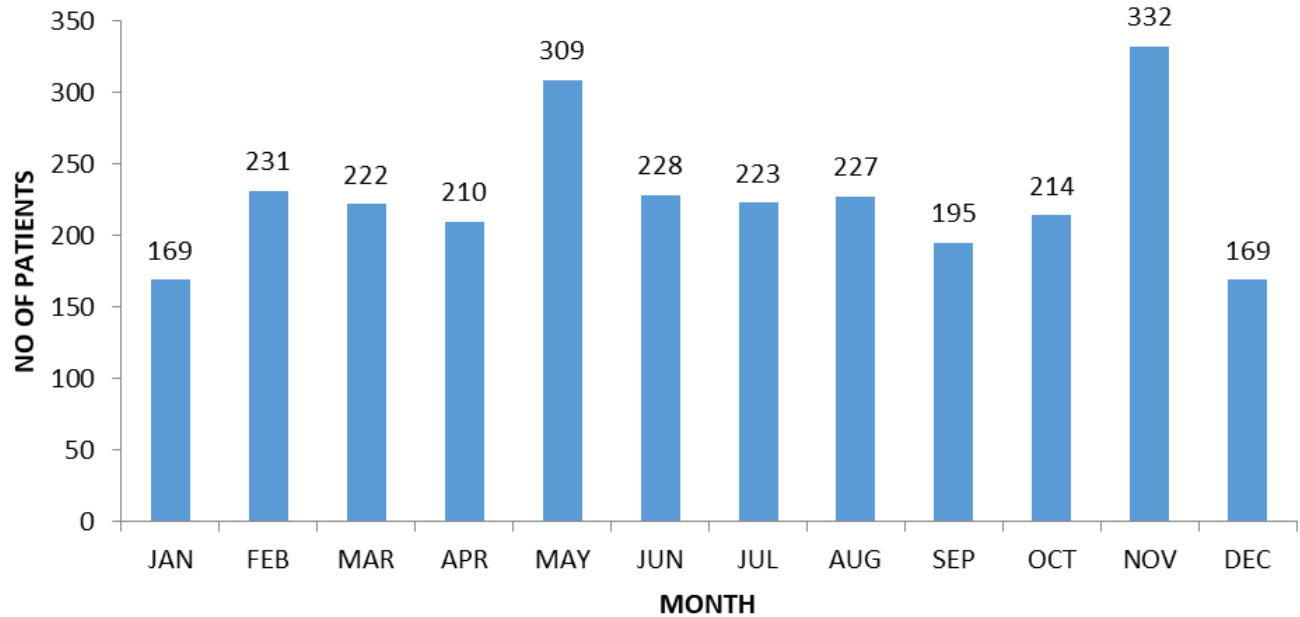
ग्यालेक्सी इन्टरनेशनल

काठमाण्डौ

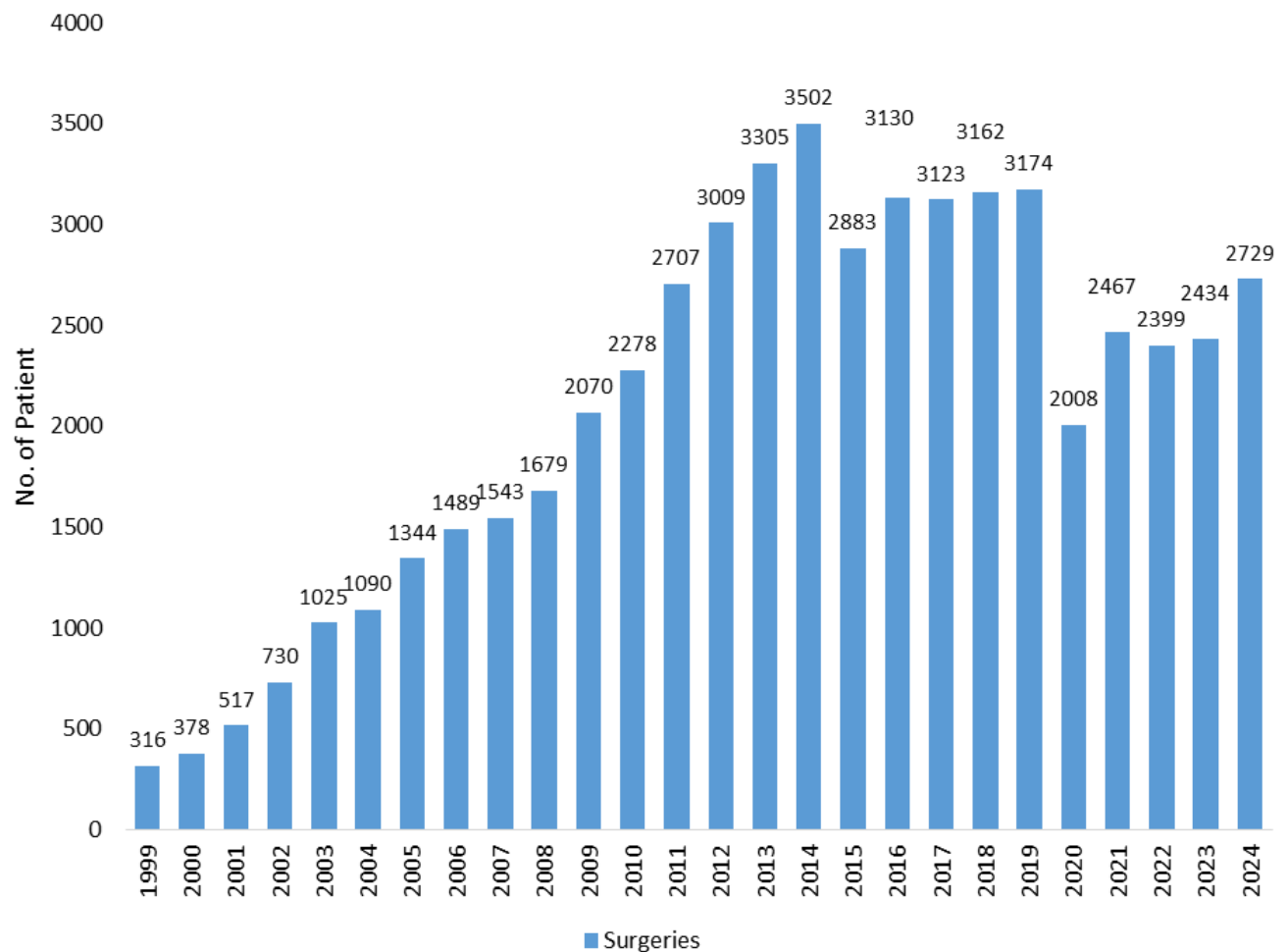


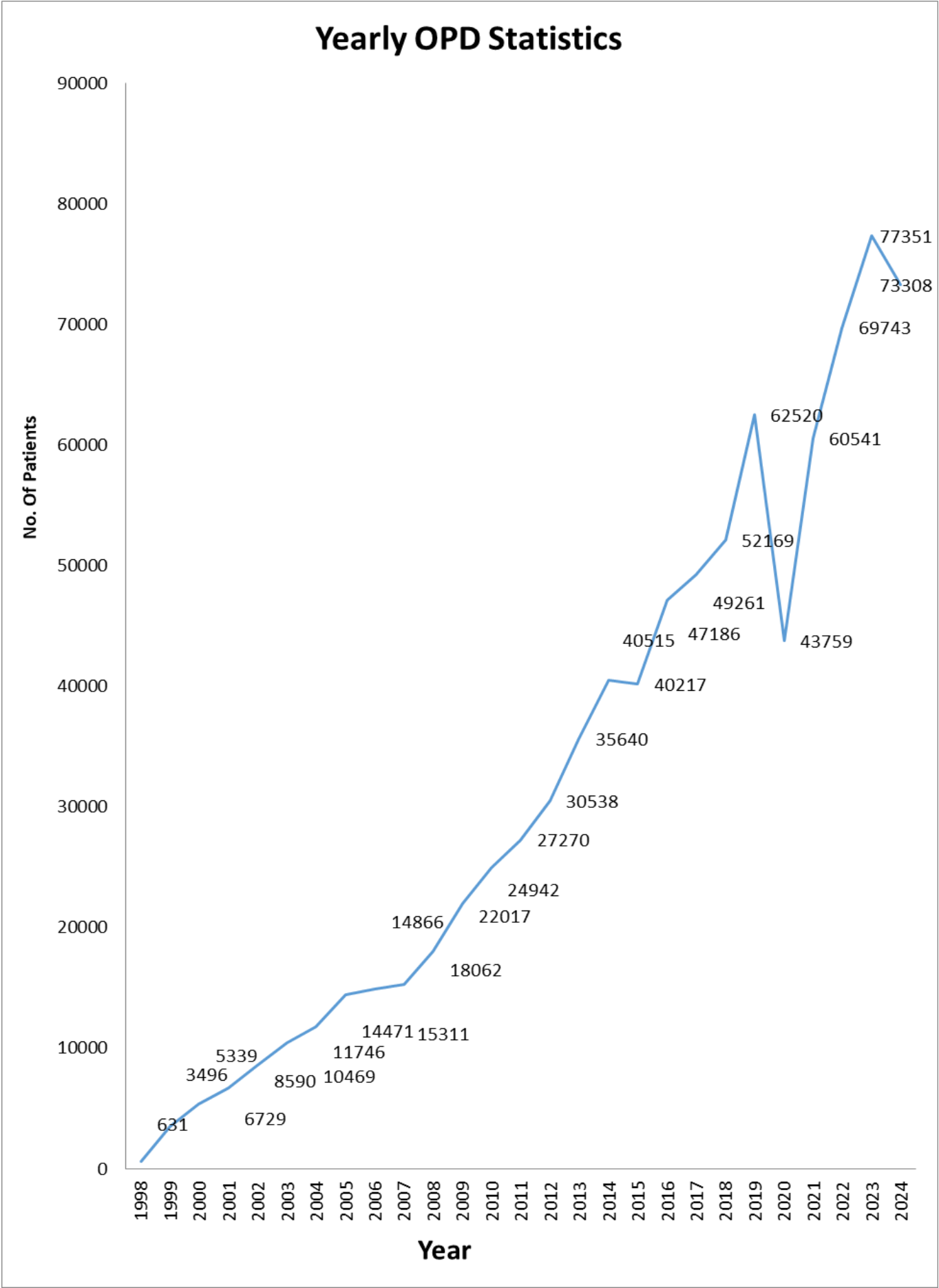


MONTHLY SURGERY

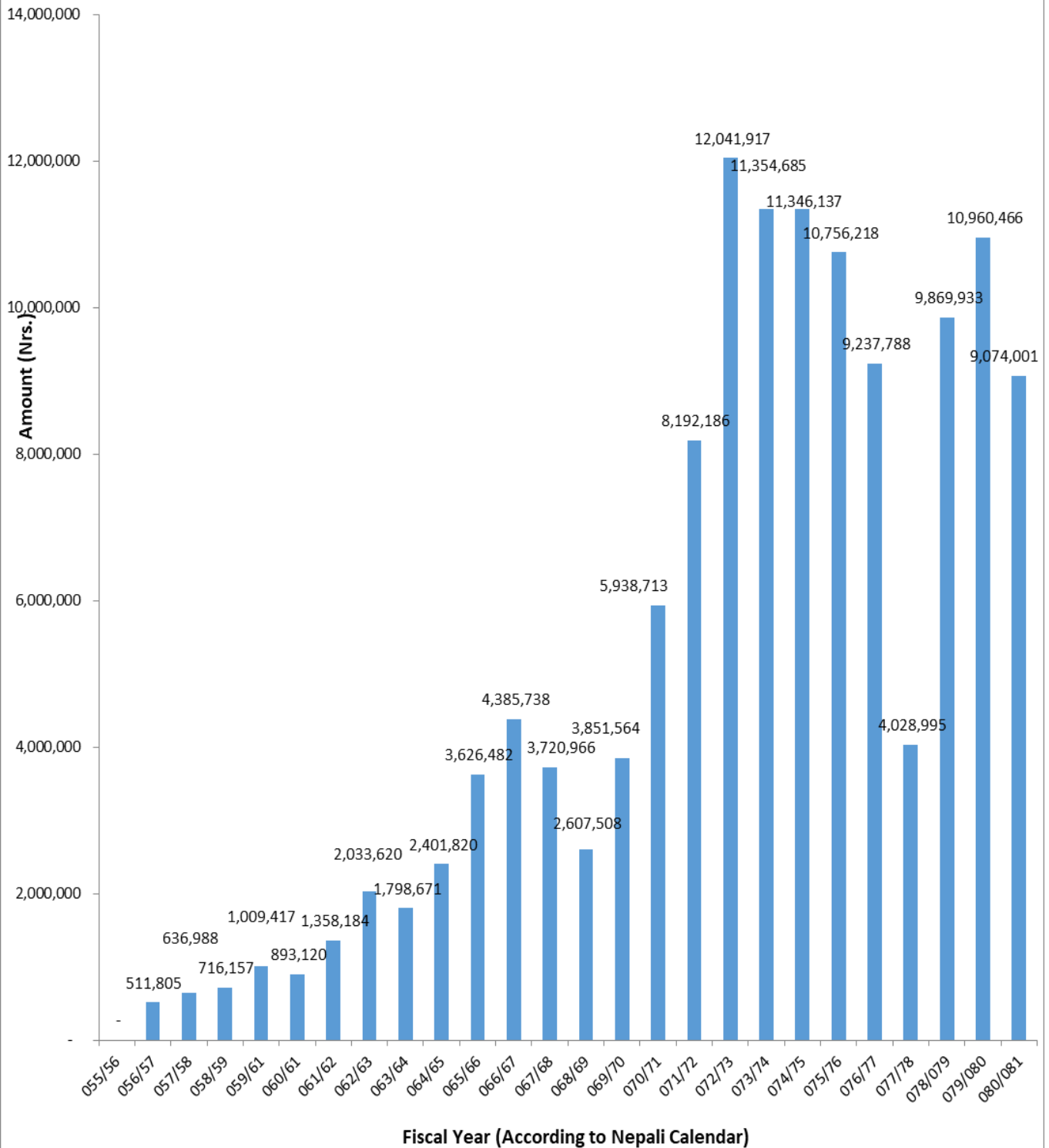


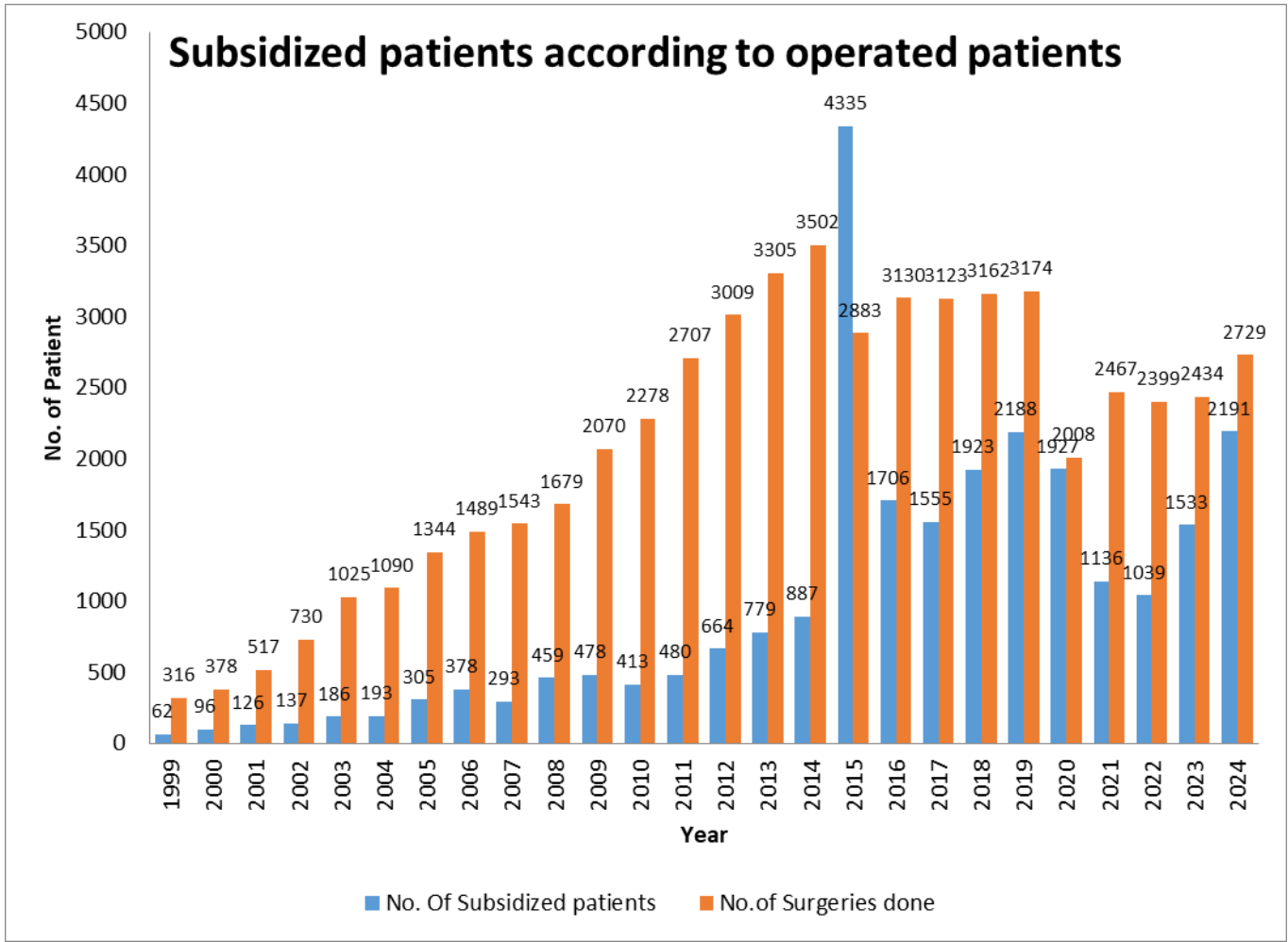
yearly Surgery





Comparative Charity Statistics





Child Charity 2024

SN	Month	No of patients	Total amt	Charity amount
1	January	11	402195	55164.99
2	February	8	332765	41820.01
3	March	6	244930	35285.01
4	April	5	174655	32617.48
5	May	8	250025	36789.98
6	June	9	378710	18720.02
7	July	10	755030	247225
8	August	9	449255	64047.5
9	September	4	94287	35602
10	October	10	400455	59020.01
11	November	5	218840	38940.01
12	December	12	490400	88750
	Total	97	4191547	753982.01

Adult Charity 2024

SN	Month	No of patients	Total amt	Charity amount
1	January	341	3065830	499087.55
2	February	134	4456795	475396.27
3	March	137	3203645	416235
4	April	118	2609025	372542.7
5	May	136	4235422	74366.41
6	June	129	2942600	205283.5
7	July	145	3223340	414910
8	August	313	4611160	365888.3
9	September	156	4336390	570560.4
10	October	103	2394610	213879.6
11	November	100	6885495	434036.1
12	December	282	3979415	362913.1
	Total	2094	45943727	4405098.93

शुभकामना

ने.अ.सं-नेपाल अर्थोपेडिक अस्पतालको २७ औं वार्षिकोत्सवको सुखद उपलक्ष्यमा अस्पताल परिवारलाई हार्दिक मंगलमय शुभकामना व्यक्त गर्न चाहन्छौं । हाडजोर्नी उपचारमा एक अलग्गै पहिचान बनाउन सफल तथा विशिष्टिकृत सेवा दिने यस अस्पतालले निरन्तर सर्वशुलभ, जनमुखि तथा गुणस्तरीय सेवा प्रदान गर्ने अस्पताल बनोस भन्ने अपेक्षा सहित हार्दिक शुभकामना व्यक्त गर्दछौं ।

क्रिटिकेयर मेडिसिन डिस्ट्रिक्ट्स

काठमाण्डौ

शुभकामना

ने.अ.सं-नेपाल अर्थोपेडिक अस्पतालको २७ औं वार्षिकोत्सवको सुखद उपलक्ष्यमा अस्पताल परिवारलाई हार्दिक मंगलमय शुभकामना व्यक्त गर्न चाहन्छौं । हाडजोर्नी उपचारमा एक अलग्गै पहिचान बनाउन सफल तथा विशिष्टिकृत सेवा दिने यस अस्पतालले निरन्तर सर्वशुलभ, जनमुखि तथा गुणस्तरीय सेवा प्रदान गर्ने अस्पताल बनोस भन्ने अपेक्षा सहित हार्दिक शुभकामना व्यक्त गर्दछौं ।

वानी मेडिको इन्टरप्राइजेज

काठमाण्डौ

शुभकामना

ने.अ.सं-नेपाल अर्थोपेडिक अस्पतालको २७ औं वार्षिकोत्सवको सुखद उपलक्ष्यमा अस्पताल परिवारलाई हार्दिक मंगलमय शुभकामना व्यक्त गर्न चाहन्छौं । हाडजोर्नी उपचारमा एक अलग्गै पहिचान बनाउन सफल तथा विशिष्टिकृत सेवा दिने यस अस्पतालले निरन्तर सर्वशुलभ, जनमुखि तथा गुणस्तरीय सेवा प्रदान गर्ने अस्पताल बनोस भन्ने अपेक्षा सहित हार्दिक शुभकामना व्यक्त गर्दछौं ।

सहारा मेडिसिन डिस्ट्रिक्ट्स प्रा.लि.

ललितपूर

**NEPAL DISABLED ASSOCIATION
NEPAL ORTHOPAEDIC HOSPITAL**

Jorpati, Kathmandu, Nepal

Statement of Income & Expenditure

For the period from 1st Shrawan, 2080 to 31st Ashad 2081 (FY 2080-81)

Amount in NRs.

Particulars	Schedule	For the year ended 31st Ashad, 2081	For the year ended 31st Ashad, 2080
Income			
Hospital Income	10	216,000,578.46	205,157,854.28
Other Income	11	7,980,506.25	8,994,595.36
Fund Received For Charity	12	2,437,925.47	5,082,897.86
Interest on Investments and Bank Deposits	13	11,632,467.98	11,009,001.64
Exchange Gain		-	1,201.70
Total of Incomes		238,051,478.16	230,245,550.84
Expenditure			
Salary & Allowance and other Expenses	14	167,000,139.92	160,535,170.27
Hospital Supplies & Expenses	15	33,916,486.14	30,697,808.30
Administration Expenses	16	15,276,346.96	13,989,628.33
Repair & Renewal	17	3,349,329.85	5,470,066.06
Charity Expenses		9,074,000.55	6,512,063.84
Contribution Expenses		1,800,000.00	2,100,000.00
Depreciation	1	7,095,667.57	6,466,169.15
Camp Expenses		-	4,448,402.47
Exchange Loss		-	-
Total of Expenditures		237,511,970.99	230,219,308.42
Excess Of Income Over Expenditure		539,507.17	26,242.42
Tax Expenses for the year		(52,836.50)	-
Prior Period Tax Expenses			-
Surplus Transfer To Capital Fund		486,670.67	26,242.42

Significant Accounting Policies & Notes on Account

18

As per our attached report of even date,

Mr. Saroj Satyal
Account Officer

Dr. Kailash Kumar
Bhandari
Medical Director

Mr. Samden Lama
Chairman

CA. Niranjana Gautam
For
Niranjana Gautam & Associates

Date: 30-01-2082
Place:





**NEPAL DISABLED ASSOCIATION
NEPAL ORTHOPAEDIC HOSPITAL**


Jorpati, Kathmandu, Nepal

Statement of Cashflow

for the year ended 31 Ashad 2081(15 July 2024)

Particulars	For the year ended 31st Ashad, 2081	For the year ended 31st Ashad, 2080
A. Cash flows from operating Activities		
Net Surplus before extraordinary item	486,670.67	26,242.42
Adjustment for:		
1. Depreciation & Amortization	7,095,667.57	6,466,169.15
2. Interest received	(11,632,467.98)	(11,009,001.64)
3. Loss (Gain) on sales of fixed assets		
Operating profit before working capital changes	(4,050,129.74)	(4,516,590.07)
1. Decrease (Increase) in Inventories	1,724,110.15	(2,304,958.39)
2. Decrease (Increase) in Accounts Receivable	(5,321,683.12)	(160,360.95)
3. Decrease (Increase) in Deposit	-	-
4. Increase (Decrease) in Current Liabilities	9,218,922.69	(11,045,753.32)
5. Increase (Decrease) in Medical & Gratuity Liabilities	9,641,522.82	9,242,704.50
Cash generated from operation	11,212,742.80	(8,784,958.23)
Interest Paid		
Net cash flow from operating activities	11,212,742.80	(8,784,958.23)
B. Cash flows from investing activities		
1. Interest received	11,632,467.98	11,009,001.64
2. (Purchase) of fixed assets	(9,060,726.65)	(7,763,632.67)
3. Sale of fixed assets	49,500.00	12,543.00
4. Decrease (Increase) in Investment	(37,657,941.05)	(13,948,416.31)
Net Cash used in investing activities	(35,036,699.72)	(10,690,504.34)
C. Cash flows from financing activities		
1. Increase (Decrease) in Capital & Other Funds		-
2. Increase (Decrease) in Fund	1,350,000.00	1,056,587.00
Net cash flow from financing activities	1,350,000.00	1,056,587.00
Net increase/(Decrease) in cash and bank (A+B+C)	(22,473,956.92)	(18,418,875.57)
Cash and bank balance at the beginning of the year	53,214,490.18	71,633,365.75
Cash and bank balance at the end of the year	30,740,533.26	53,214,490.18



Mr. Saroj Satyal
Account Officer


Dr. Kailash Kumar
Bhandari


Mr. Samden Lama
Chairman

As per our attached report of even date


CA. Nirajan Gautam
for
Nirajan Gautam &
Associates



Date: 30-01-2082
Place:



**NEPAL DISABLED ASSOCIATION
NEPAL ORTHOPAEDIC HOSPITAL**
Jorpati, Kathmandu, Nepal
Statement of Financial Position
As at 31 Ashad 2081 (15 July 2024)

Amount in NRs.

Assets	Schedule	Ashad 31, 2081 (15 July 2024)	Ashad 31, 2080 (16 July 2023)
Non Current Assets:			
Fixed Assets & Intangible Assets	1	126,772,240.46	124,856,681.40
Investment	2	124,237,770.13	86,579,829.08
Current Assets:			
Closing Stock	3	8,524,523.49	10,248,633.64
Sundry Debtors and Advance	4	7,312,242.89	1,990,559.77
Deposits	5	109,000.00	109,000.00
Cash and Bank Balance	6	30,740,533.26	53,214,490.18
Total Assets		297,696,310.24	276,999,194.07

Fund & Liability	Schedule	Ashad 31, 2081 (15 July 2024)	Ashad 31, 2080 (16 July 2023)
Hospital Fund & Accumulated Reserves :			
Hospital Fund, Accumulated & Other Capital Reserves	7	190,463,050.30	188,626,379.64
Non Current Liabilities:			
Staff Gratuity Fund		61,736,321.00	52,520,158.68
Staff Medical Fund		2,905,604.00	2,686,320.00
Home leave & Sick Leave Payable Fund		18,487,891.00	18,281,814.50
Total Non Current Liabilities		83,129,816.00	73,488,293.18
Current Liabilities :			
Sundry Creditors	8	15,067,226.29	4,857,871.94
Patient Deposit	9	3,810,557.00	1,413,000.00
Other Payable	9	2,773,335.70	2,243,980.56
Staff Welfare fund	9A	-	3,500,000.00
Provisions	9A	2,452,324.95	2,869,668.75
Total Current Liabilities		24,103,443.94	14,884,521.25
Total Capital & Liabilities		297,696,310.24	276,999,194.07

Significant Accounting Policies & Notes on Account

18

Mr. Saroj Satyal
Account Officer

Dr. Kailash Kumar Bhandari
Medical Director

Mr. Samden Lama
Chairman

CA. Niranjana Gautam
for
Niranjana Gautam & Associates

Date: 30/06/2082
Place: Kathmandu

As per our attached report of even date



शुभकामना

ने.अ.सं-नेपाल अर्थोपेडिक अस्पतालको २७ औं वार्षिकोत्सवको सुखद उपलक्ष्यमा अस्पताल परिवारलाई हार्दिक मंगलमय शुभकामना व्यक्त गर्न चाहन्छौं । हाडजोर्नी उपचारमा एक अलग्गै पहिचान बनाउन सफल तथा विशिष्टिकृत सेवा दिने यस अस्पतालले निरन्तर सर्वशुलभ, जनमुखि तथा गुणस्तरीय सेवा प्रदान गर्ने अस्पताल बनोस भन्ने अपेक्षा सहित हार्दिक शुभकामना व्यक्त गर्दछौं ।

फ्रेस्या टेडर्स

काठमाण्डौ

Do You Want To Support Nepal Orthopaedic Hospital ???

The Hospital humbly request individuals and organizations to consider donation to the hospital, so that more service and more charity can be provided to the needy.

Please contact hospital administration directly by e-mail or phone or correspondence.

If you want to help the hospital or support the patients for their treatment,

Please correspond to the following address as :

NDA - Nepal Orthopaedic Hospital

Gokarneswor Municipality -06, Jorpati, Kathmandu, Nepal

Tel.: 00977-1-4911725, 4911274, 4910505

E-mail: neporth@mos.com.np, Website: www.noh.org.np

Our Services

- Outpatient and Inpatient service
- ICU/ Post-operative care
- Extended Hospital service (Paying Clinic)
(Morning 8-9:30 AM, Evening 4-6 PM)
- Surgery
 - All kinds of orthopaedic and trauma surgery with state of art technology
 - Total Hip and Knee replacement
- Physiotherapy
- 24 hrs. Pharmacy
- 24 hrs. X-ray (CR/DR)
- 24 hrs. Laboratory Services
- PCL Reconstruction
- ACL Reconstruction
- Arthroscopy Surgery
- Meniscus Surgery
- Social service
- Emergency Service (24 Hours)
- Free Surgical camps (Outreach health camp)
- ECHO and Cardiac service
- Ultrasound
- Bone Densitometry
- General Physician Service
- Psychiatric service
- CT/MRI
- Services since 1998 to 2024

Nepal Orthopaedic Hospital Location on Google Map

